

# Guillain–Barré Syndrome developing in a patient with Graves' Disease

Anirban Majumder<sup>1</sup> and Sagar Basu<sup>2</sup>

<sup>1</sup>Endocrinology Department, KPC Medical College, West Bengal University of Health Sciences, Kolkata, India

<sup>2</sup>Neurology Department, KPC Medical College, West Bengal University of Health Sciences, Kolkata, India

## Abstract

Graves' disease (GD) and Guillain-Barré syndrome (GBS) are both autoimmune disorders and are triggered by interactions between genetic and environmental factors. GBS in patients who suffer from other autoimmune diseases is rarely reported, and the development of atypical GBS with cranial nerve involvement in a patient with GD has never been previously reported. Herein, we report a patient with GD and a rare form of pharyngo-cervico-brachial variety of GBS.

**Key words:** Graves' disease, Guillain-Barré syndrome, pharyngo–cervico–brachial variety

## INTRODUCTION

Graves' disease (GD) is a disorder with three major manifestations: hyperthyroidism with diffuse goitre, ophthalmopathy and dermatopathy.<sup>1</sup> The homeostatic mechanism that normally adjusts hormone secretion to meet the needs of peripheral tissue is disrupted due to immune reactivity. Autoantibodies directed to the TSH receptor (TRAb), thyroid peroxidase (TPO), and thyroglobulin (TG) are strongly associated with GD.<sup>2</sup> Among them TRAb is the stimulating antibody. Thus, while the basic cause of Graves' disease is not well understood, an immunoglobulin or a family of immunoglobulins directed against the TSH receptor mediates the thyroid stimulation and is also responsible for the related connective tissue manifestations of GD.

Guillain-Barré syndrome (GBS) is typically characterized by symmetric ascending weakness, predominantly proximal than distal, with hyporeflexia or areflexia without sensory or sphincter involvements. Sometimes cranial nerves and respiratory muscles are also involved. The illness progresses to its nadir within 4 weeks. Cerebrospinal fluid (CSF) study shows "albumino-cytologic dissociation" in 90% of cases.<sup>3</sup> It is an acute inflammatory demyelinating polyneuropathy with evidence of the immune attack directed at peripheral myelin sheath with secondary axon loss.<sup>3</sup> Various atypical forms of GBS have been described,<sup>4</sup> one of which is the pharyngo-cervico-brachial variety which is very rare. This particular variant has not been reported in previous literature in association with GD.

## CASE

FB, a 35-year-old Indian female, presented with a gradually enlarging goitre for the past 1 year accompanied by palpitations, tremor and weight loss. She also admitted heat intolerance, increased appetite, sleeplessness and

amenorrhea for 4 months. However, she did not complain of any visual disturbance or hoarseness of voice and did not consult any physician for her complaints. With this background, the patient developed sudden onset of dysarthria with nasal intonation of speech and nasal regurgitation of liquids about 2 weeks before presentation. She denied any weakness of limbs and sphincter disturbances. There was no history of visual disturbances, other cranial nerve involvement, headache, vomiting, fever, skin rash or recent vaccination. No history of diurnal variation of symptoms was found.

She looked anxious and restless. She was found to be 146 cm in height, 38 kg in weight and had a regular pulse of 128/min. We also observed fine postural tremor, staring look, lid-lag and lid retraction, although exophthalmos and dermatopathy were absent. The thyroid gland was diffusely enlarged (Grade 2), soft to feel with a bruit. Neurological examination revealed bulbar palsy with involvement of 9th and 10th cranial nerves. There was mild weakness of neck flexors (IV/V) and proximal muscles of upper limbs (IV/V). Deep tendon reflexes were normal in lower limbs, but hypo-reflexic in upper limbs.

Investigations revealed Hb of 12.6 gm% TLC 7500/cumm with normal differential counts, fasting plasma glucose 94 (70-99 mg/dl), urea 19 (7 to 20 mg/dl) and creatinine 0.6 (0.6 to 1.2 mg/dL). Her thyroid profile showed T3 2.6 (0.80-1.8 ng/ml), T4 19.2 (4.6-12 ug/dl) and TSH <0.1 (0.45-4.12 mIU/ml), while Tc-99 m scan indicated increased and uniform uptake. Her anti-TSH receptor antibody (TRAb) and Anti-TPO antibody were also strongly positive and suggestive of Graves' disease.

Magnetic Resonance Imaging (MRI) of the brain was normal. Electrophysiological studies showed only ill-persistent "F" waves in upper limbs, suggestive of demyelination of proximal region. Repetitive nerve

stimulation test (RNST) was normal. CSF study showed protein level of 155mg/dl with normal glucose values and cell count (8 cell/ml- all lymphocytes) – so called "albumino-cytological dissociation". All these findings were suggestive of atypical variety of GBS – the rare "pharyngo- cervico- brachial" variety.

Fortunately, there was no further progression of weakness, dysarthria, nasal intonation of speech and the patient improved over the next 4 weeks without any specific therapy. Her GD was treated with an antithyroid drug. Methimazole was started with 20 mg dose and was followed by thyroid function, blood counts and liver function tests every 2 months. She was scrupulously alerted to stop the medication if there were symptoms suggestive of agranulocytosis or hepatic injury.

She became euthyroid in the next 6 months and the methimazole dose was reduced to a maintenance dose of 5 mg daily. The neurological symptoms were most severe during the initial presentation, progressively improving on follow up and almost complete recovery occurred over next 4 weeks with improvement of thyroid function but before the normalisation of FT4 level. She was not treated with intravenous immunoglobulin (IVIG) as her neurological abnormalities were improving day-by-day, and also because she could not afford the cost of this highly priced therapy.

## DISCUSSION

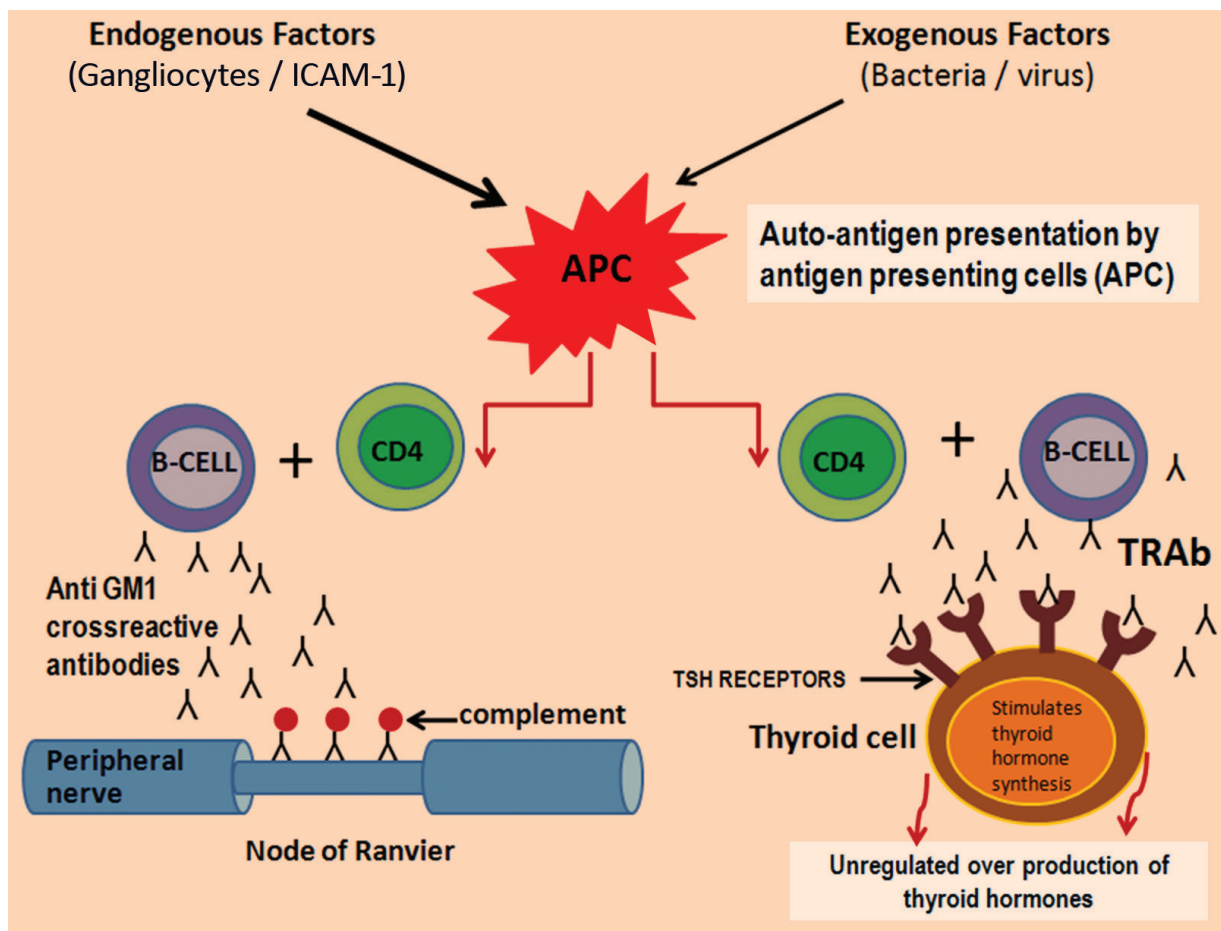
The case presented is characterized by an association between GD and GBS. GD is the major immunologically mediated form of hyperthyroidism and multiple factors contribute to the etiology of GD, including a host of genetic as well as environmental factors. It is a slowly progressive disease that involves the activation and recruitment of TSH receptor-specific T and B cells. This activation eventually results in the production of stimulatory antibodies (TRAb) directed against the TSH receptors on the thyroid follicular cells and stimulate thyroid hormone production.<sup>2</sup> Increased incidence of GD among members of a family indicates that genetic factors might also play an important role. The risk of developing the disease is higher among individuals with a major histocompatibility complex (MHC) class-II haplotype of HLA-B8, HLA-DR3 or with DQA1\*0501 haplotype and in contrast, the expression of HLA DR  $\beta$ 1\*07 appears to confer protection. As with other autoimmune diseases, environmental factors have also been suspected in the etiology of GD. There are a number of potential mechanisms by which an environmental agent could trigger an autoimmune response and molecular mimicry is one of the commonly invoked mechanisms for the induction of autoimmunity. The bacteria, *Y. enterocolitica* has been postulated to play a role in the induction of GD via molecular mimicry.<sup>2</sup> Strongly positive TRAb and TPO antibody in our patient confirms the diagnosis of GD but we could not check HLA type in our medical set-up. She did not have any history (fever, vomiting, diarrhea, etc.) suggestive of recent *Y. enterocolitica* infection.

GBS, an acute inflammatory demyelinating polyneuropathy, is a disorder of the peripheral nervous system. One of the hallmarks of the pathogenesis is a

significantly elevated cerebrospinal fluid (CSF) protein level. It was estimated 155 mg/dl in our subject as against 20-40 mg/dl among normal subjects. This elevated CSF protein was not associated with any rise in cell count and 8 cells/ml was well within normal reference range of 0-10 cells/ml. A non-specific rise in total CSF protein concentration is because of protein leakage from blood through the blood-nerve barrier.<sup>5</sup> GBS is thought to be associated with autoimmune response against neuro-specific molecules. Autoantibodies directed against cell adhesion proteins localized at Ranvier's nodes have been suggested as a possible target, but no reliable corresponding autoantibodies have been found. Proteome analysis suggests bacteria and/or virus infections as possible autoimmune triggers as GBS patients are more immunopositive with polyinfections. Recently, it has been suggested that the primary peripheral nervous system damage is being initiated as an innate immunity-associated local inflammation following neurotropic viruses egress, and the autoantibody production is a complementary secondary process.<sup>5</sup> However, we did not find any suggestive history of recent viral or bacterial infection in our subject.

Transient multiple lower cranial nerve palsy, mild neck flexors and proximal upper limb weakness along with ill-persistent "F" waves in upper limbs and albumino-cytologic dissociation suggest atypical variety of GBS – the pharyngo-cervico-brachial variety. There is no single serological marker for this variety of GBS, although sometimes it is associated with Ig anti-ganglioside antibody (anti-GM1 and anti-GT1A).<sup>5</sup> Occasionally this variety overlaps with Miller-Fisher syndrome, where ophthalmoparesis is also seen along with ataxia. Miller-Fisher syndrome is associated with anti GQ1 antibody and the above two antibodies often cross-react with each other.<sup>6</sup>

Although GD and GBS are autoimmune disorders, simultaneous occurrence is a rarity. The exact mechanism of this association is not well understood but the autoimmunity is the leading cause of development of both the diseases. After evaluation of literature, we found 3 possible explanations for simultaneous presentation of GD and GBS (Figure 1). First, the plasma membranes of both thyrocytes and neuronal cells are rich in gangliosides.<sup>7</sup> The gangliosides may cause production of autoantibodies leading to GBS and certain neuropathies. The pathophysiological mechanism in our patient, may be the consequence of an immunological interaction of autoantibodies against thyrocytes and also neuronal cells. Second, circulating form of intercellular adhesion molecule (ICAM) is significantly elevated in certain autoimmune diseases.<sup>8</sup> High serum levels of ICAM- 1 is associated with autoimmune thyroid disease, both GD and Hashimoto's disease.<sup>9</sup> Interleukin -17 and ICAM-1 polymorphisms have significant association with GBS and their enhanced expressions have possible role in GBS development.<sup>10</sup> However, circulating form of ICAM is present in normal persons; and elevated levels in certain immune mediated diseases is not necessarily pathogenic and may be nonspecific markers of immune dysregulation. Third, in the backdrop of susceptible genetic background, environmental factors such as bacteria and/or viruses are often partially accountable for



**Figure 1.** Molecular mechanisms of simultaneous presentation of GD and GBS.

the development of autoimmune diseases. In GD, *Yersinia*-derived T cell superantigens and B cell mitogens might act independently or in combination to activate T cells and/or B cells, resulting in preferential expansion of B cells recognizing cross-reactive epitopes on TSHR and *Yersinia*.<sup>2</sup> On the other hand, *Campylobacter jejuni*, Epstein-Barr virus, Cytomegalovirus, Zika virus and *Mycoplasma pneumoniae* are thought to be able to trigger GBS. The antibodies to these infective agents have an affinity for GM1 and GT1A gangliosides, which are located in the paranodal areas and the nodes of Ranvier in peripheral nerves and molecular mimicry mechanisms and cytokine stimulation are implicated in the pathogenesis of GBS.<sup>5</sup> Though the infective agents involved in the pathogenesis of GD and GBS are different, a common infective aetiology may be a possible explanation for simultaneous occurrence of GD and GBS.

Lastly, it is important to note that with the rise in thyroid hormone levels the frequency and severity of GBS also increases.<sup>11</sup> Further investigation into similar cases could reveal the relationship of these autoimmune diseases. GBS, provoked by antecedent infection (postinfectious GBS), has been reported in patient who suffered from methimazole-induced agranulocytosis with GD.<sup>12</sup> However, our subject was newly diagnosed and was not treated with any antithyroid drug at the time of presentation. In this clinical case, the concomitant presence of 2 rarely associated

autoimmune disorders is demonstrated. We know the limitations of the report of our case such as not having measured anti-ganglioside antibodies and serum level of ICAM and the inability to demonstrate a common infective aetiology of the case. Despite this, it is the first case described in literature that associates the pharyngo-cervico-brachial variety of GBS with GD.

## CONCLUSION

Association of GBS with one or other autoimmune diseases has been reported rarely. GBS and GD apparently have a common autoimmune pathophysiology. In the clinical case described above, the concomitant presentation of pharyngo-cervico-brachial variety of GBS with GD is a rare clinical situation.

### Ethical Consideration

Patient consent was obtained before submission of the manuscript.

### Statement of Authorship

All authors certified fulfilment of ICMJE authorship criteria.

### Author Disclosure

The authors declared no conflict of interest.

### Funding Source

None.

## References

- DeGroot LJ. Graves' disease and the manifestations of thyrotoxicosis. In: Feingold KR, Anawalt B, Boyce A, et al., editors. Endotext [Internet]. South Dartmouth (MA) L MDText.com, Inc.;2000-2015 Jul 11.
- Prabhakar BS, Bahn RS, Smith TJ. Current perspective on the pathogenesis of Graves' disease and ophthalmopathy. *Endocr Rev.* 2003;24(6): 802-35. PMID: 14671007. <https://doi.org/10.1210/er.2002-0020>.
- Olshansky A. Diagnosis and treatment of Guillain-Barre syndrome. *Virtual Mentor.* 2007;9(8):552-4. <https://doi.org/10.1001/virtualmentor.2007.9.8.cpr11-0708>.
- Ropper AH. Further regional variants of acute immune polyneuropathy. Bilateral weakness or sixth nerve paresis with paresthesias, lumbar polyradiculopathy, and ataxia with pharyngeal-cervical-brachial weakness. *Arch Neurol.* 1994;51(7):671-5. PMID: 8018039.
- Ziganshin RH, Ivanova OM, Lomakin YA, et al. The pathogenesis of the demyelinating form of Guillain-Barre Syndrome (GBS): Proteo-peptidomic and immunological profiling of physiological fluids. *Mol Cell Proteomics.* 2016;15(7):2366-78. PMID: 27143409. PMID: PMC4937510. <https://doi.org/10.1074/mcp.M115.056036>.
- Nagashima T, Koga M, Odaka M, Hirata K, Yuki N. Continuous spectrum of pharyngeal-cervical-brachial variant of Guillain-Barré syndrome. *Arch Neurol.* 2007;64(10):1519-23. PMID: 17923636. <https://doi.org/10.1001/archneur.64.10.1519>.
- Ahn SW, Kim SH, Park BS, et al. Concurrence of multifocal motor neuropathy and Hashimoto's thyroiditis. *J Clin Neurol.* 2011;7(3):168-72. PMID: 22087213 PMID: PMC3212605. <https://doi.org/10.3988/jcn.2011.7.3.168>.
- Martin S, Rieckmann P, Melchers I, et al. Circulating forms of ICAM-3 (cICAM-3). Elevated levels in autoimmune diseases and lack of association with cICAM-1. *J Immunol.* 1995;154(4):1951-5. PMID: 7836774.
- Lee JH, An MA, Jeon JS, et al. Circulating intercellular adhesion molecule-1(ICAM-1) in sera of patients with Graves' disease and Hashimoto disease. *Korean J Intern Med.* 1995;10(1):10-5. PMID: 7626551. PMID: PMC4532030.
- Kharwar NK, Prasad KN, Singh K, Paliwal VK, Modi DR. Polymorphisms of IL-17 and ICAM-1 and their expression in Guillain-Barré syndrome. *Int J Neurosci.* 2007;127(8):680-7. PMID: 27595159. <https://doi.org/10.1080/00207454.2016.1231186>.
- Huang Y, Ying Z, Chen Z, et al. Thyroid hormone level is associated with the frequency and severity of Guillain-Barré syndrome. *Int J Neurosci.* 2017;127(10):893-9. PMID: 28042737. <https://doi.org/10.1080/00207454.2016.1278541>.
- Cho YY, Joung JY, Jeong H, et al. Postinfectious Guillain-Barre syndrome in a patient with methimazole-induced agranulocytosis. *Korean J Intern Med.* 2013;28(6):724-7. PMID: 24307850. PMID: PMC3847000. <https://doi.org/10.3904/kjim.2013.28.6.724>.

Authors are required to accomplish, sign and submit scanned copies of the JAFES Author Form consisting of: (1) Authorship Certification, that authors contributed substantially to the work, that the manuscript has been read and approved by all authors, and that the requirements for authorship have been met by each author; (2) the Author Declaration, that the article represents original material that is not being considered for publication or has not been published or accepted for publication elsewhere, that the article does not infringe or violate any copyrights or intellectual property rights, and that no references have been made to predatory/suspected predatory journals; (3) the Author Contribution Disclosure, which lists the specific contributions of authors; and (4) the Author Publishing Agreement which retains author copyright, grants publishing and distribution rights to JAFES, and allows JAFES to apply and enforce an Attribution-Non-Commercial Creative Commons user license. Authors are also required to accomplish, sign, and submit the signed ICMJE form for Disclosure of Potential Conflicts of Interest. For original articles, authors are required to submit a scanned copy of the Ethics Review Approval of their research as well as registration in trial registries as appropriate. For manuscripts reporting data from studies involving animals, authors are required to submit a scanned copy of the Institutional Animal Care and Use Committee approval. For Case Reports or Series, and Images in Endocrinology, consent forms, are required for the publication of information about patients; otherwise, appropriate ethical clearance has been obtained from the institutional review board. Articles and any other material published in the JAFES represent the work of the author(s) and should not be construed to reflect the opinions of the Editors or the Publisher.



**A new venue for publishing your original articles.**  
**Visit [www.ASEAN-endocrinejournal.org](http://www.ASEAN-endocrinejournal.org) for**  
**Instructions to Authors.**