

Dermopathy, Acropachy and Orbitopathy in Graves Disease

James K. Young and Michael L. Villa

Section of Endocrinology, Diabetes and Metabolism, Department of Internal Medicine,
 St. Luke's Medical Center, Quezon City, Philippines

A 56-year-old Filipino male presented with bilateral lower limb swelling. The patient was a known smoker with a one-year history of Graves' disease. He was initially treated with methimazole for control of thyrotoxicosis. Five months prior to consultation, he was given oral radioactive iodine (Iodine-131) for the definitive treatment of his thyroid disease. The patient had no clinically detectable extrathyroidal manifestations of Graves' disease at that time. However, within 3 months after definitive treatment, he developed extensive swelling of both lower extremities, notably seen on the pretibial area; mild to moderate ophthalmopathy; and drumstick swelling of the fingers. He also developed symptoms of hypothyroidism. Eye examination revealed bilateral exophthalmos, with Hertel exophthalmometer reading of 22 on the right and 24 on the left eye; edema of the upper eyelids; chemosis; and bilateral conjunctival injection (Figure 1 and 2). The patient also had flesh-colored nodules on his upper arms (Figure 3). The most prominent physical finding was swelling of both lower extremities. Examination of the pretibial area revealed thickened skin, with firm, verrucous, hyperkeratotic nodules surrounded by deep fissures and folds (Figure 4). Thyroid function tests showed a thyrotropin level of 10 μ IU/mL (normal value 0.4 to 5.0) and a free thyroxine level of 0.5 ng/dL (normal value 0.8 to 1.9). His TSH receptor antibody (TRAb) was elevated at 28.8 U/L (normal value 0 to 1). Skin biopsy of the lesions located at the arm and at the lower extremity showed myxedematous change in the superficial dermis with abundant dermal mucin, characteristic of pretibial myxedema. Plain radiograph of the fingers was normal. Magnetic resonance imaging (MRI) of the orbit showed proptosis of both globes, with prominence of intraconal and extraconal fat. Levothyroxine was started, which subsequently resulted in a significant improvement of hypothyroidism. The patient was also given steroid injections, topical steroids, and decongestive physiotherapy on his lesions at the lower extremities and upper arm for three months. Oral prednisone was also given which resulted in some improvement of the ophthalmopathy. The patient was followed for 1 year with note of complete resolution of his dermal lesions (Figure 5).

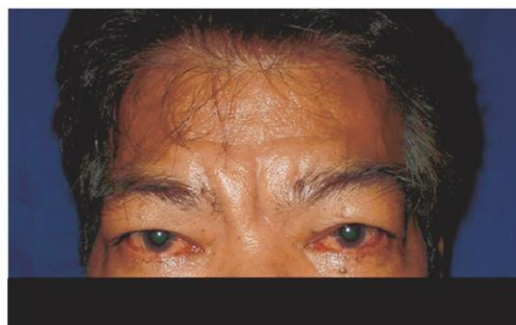

Figure 1. Graves ophthalmopathy showing bilateral exophthalmos with chemosis and conjunctival injection.

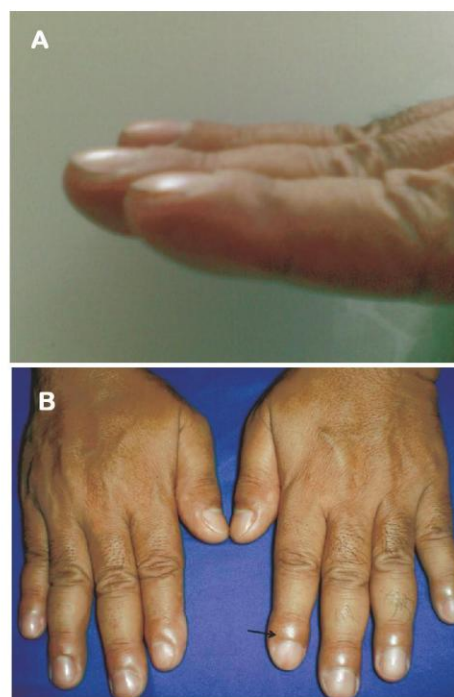


Figure 2. Graves acropachy showing clubbing of fingers, with a Lovibond angle of greater than 180° (A). Accentuated nail curvature and periungual skin thickening (arrow) was also noted (B).

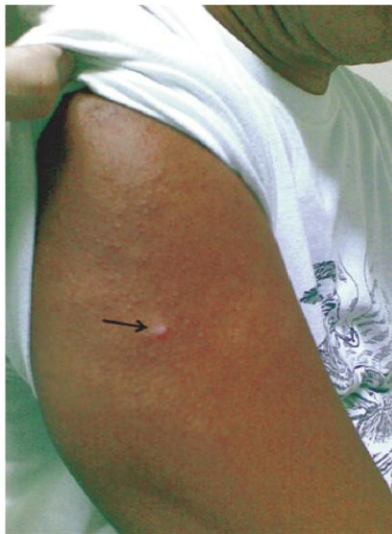

Figure 3. Graves dermopathy showing flesh colored nodules on the upper arm (arrow).

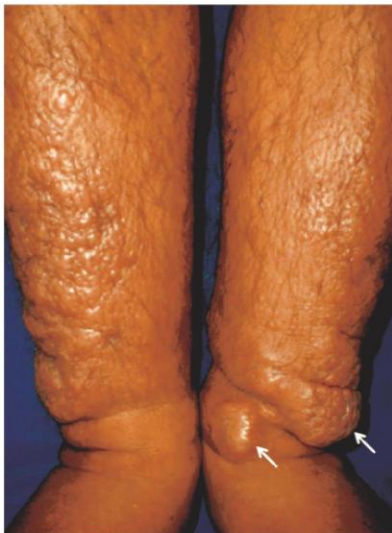

Figure 4. Skin-colored to yellowish, waxy indurated papules; verrucous nodules and plaques (arrow) with the characteristic *peau d orange* appearance of both lower extremities demonstrating Graves dermopathy.

Graves' disease is an autoimmune disorder of the thyroid gland with characteristic peripheral manifestations. The most common extrathyroidal manifestation is ophthalmopathy, present in 50% of patients¹⁻²; followed by dermopathy in 4-5%³⁻⁵; and acropachy in 1%.⁶ The triad of dermopathy, acropachy and exophthalmos occurs very rarely, as it is seen in less than 1% of patients with Graves' disease.⁷ The treatment of Graves' ophthalmopathy is aimed to alleviate symptoms, and prevent disease progression and serious ocular sequelae. Treatment options include systemic glucocorticoid therapy, orbital radiotherapy and orbital surgical decompression.⁸⁻⁹ The goal of treatment of Graves' dermopathy is to decrease hyaluronic acid production by the fibroblast. This includes

intralesional steroid injection; topical steroid with occlusive dressings and compression; systemic steroids; surgical excision; and immunotherapy.^{2-3,10} Graves' acropachy generally does not require treatment.²

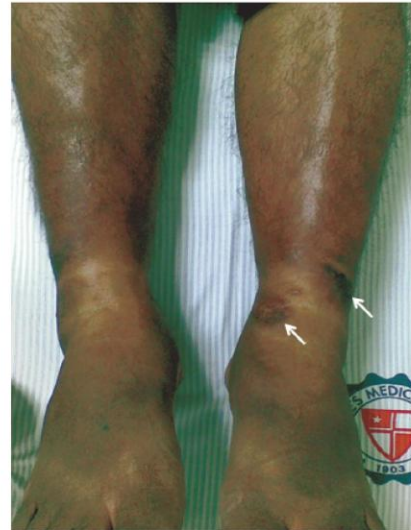

Figure 5. Resolution of dermopathy after intra-lesional steroid treatment and decompression physiotherapy.

References

1. Bartalena L, Tanda ML. Graves' Ophthalmopathy. *N Engl J Med.* 2009 Mar 5;360(10):994-1001.
2. Marino M, Chiovato L, Pinchera A. Graves' Disease. In: Jameson JL, De Groot LJ, eds. *Endocrinology Adult and Pediatric.* 6th Edition. Philadelphia: Saunders; 2010:1527-71.
3. Davies TF, Larsen PR. Thyrotoxicosis. In: Kronenberg HM, Melmed S, Polonsky KS, Larsen PR, eds. *Williams Textbook of Endocrinology.* 11th Edition. Philadelphia: Saunders; 2008:333-75.
4. Fatourehchi V, et al., Dermopathy of Graves' disease (pretibial myxedema): Review of 150 cases. *Medicine (Baltimore).* 1994 Jan;73(1):1-7.
5. Tiu SC, Choi CH. Elephantiasic thyroid dermopathy. *Hong Kong Med J.* 2006 Apr;12(2):159-60.
6. Fatourehchi V, et al., Thyroid acropachy: Report of 40 patients treated at a single institution in a 26-year period. *J Clin Endocrinol Metab.* 2002 Dec;87:5435-41.
7. Anderson CK, Miller OF 3rd. Triad of exophthalmos, pretibial myxedema and acropachy in a patient with Graves' disease. *J Am Acad Dermatol* 2003 Jun;48(6):970-2.
8. Bartalena L, et al., Consensus statement of the European Group on Graves' orbitopathy (EUGOGO) on management of GO. *Eur J Endocrinol.* 2008 Mar;158(3):273-85.
9. Dickinson J, Perros P. Thyroid-associated orbitopathy: Who and how to treat. *Endocrinol Metab Clin North Am.* 2009 Jun;38(2):373-88.
10. Antonelli A, et al., Results of high-dose intravenous immunoglobulin treatment of patients with pretibial myxedema and Basedow's disease: Preliminary findings. *Clin Ter.* 1992 Sep;141(9 Pt 2):63-8.