

Comparison of Modified Rose Method of Thyroid Palpation Versus Other Methods for the Detection of Retrosternal and Nodular Goitre

Santosha Kumar Pattashanee,¹ Gopal Puri,¹ Kamal Kataria,¹ Piyush Ranjan,¹ Anita Dhar,¹
Anurag Srivastava,¹ Surabhi Vyas,² Yashdeep Gupta,³ RM Pandey⁴

¹Department of Surgical Disciplines, All India Institute of Medical Sciences, New Delhi, India

²Department of Radiology, All India Institute of Medical Sciences, New Delhi, India

³Department of Endocrinology, All India Institute of Medical Sciences, New Delhi, India

⁴Department of Biostatistics, All India Institute of Medical Sciences, New Delhi, India

Abstract

Objectives. This is a diagnostic test research study to evaluate the various existing methods of thyroid examination and their comparison with the novel modified Rose method. It also aims to measure inter-examiner variation in clinical findings based on the level of education and training, as compared to ultrasonography.

Methodology. This cross-sectional study was conducted at a tertiary care hospital with 83 patients presenting to surgery OPD with neck swelling. Each patient was examined by one trained Junior Resident and a Surgery Consultant with all the four methods and with ultrasonography. Data was analysed by Stata-14, agreement between the two categorical variables was assessed by Kappa. In case of continuous variable agreement was assessed by Intra class correlation and Bland-Altman plot.

Results. Modified Rose method by the consultant has the highest sensitivity (98%) and diagnostic odds (210) as compared to others but its specificity ranges from 46.7-91.1% to diagnose retro-sternal extension of a goiter. It has 93.98% agreement for identification of nodules. It has a high specificity (Consultant - 100%, Resident - 95.5%) with relatively lower sensitivity (Consultant - 94%, Resident - 86.8%) to diagnose solitary thyroid nodule (STN) but the sensitivity and specificity for diagnosing a multinodular goitre (MNG) was high. However, the highest sensitivity to diagnose STN was highest with Crile's method, but specificity was low. Lahey's method was a better clinical method to palpate lymph nodes compared to the other three.

Conclusion. Examination in modified Rose's position is a better method of clinical examination of thyroid especially in patients with occult substernal extension. Lahey's method is a better method to examine cervical lymph nodes.

Key words: clinical thyroid examination, modified Rose position, modified Rose method, Kappa statistic, retro-sternal extension

INTRODUCTION

The burden of thyroid diseases is on the rise including both benign and malignant conditions.¹ Thirty percent of Indians suffer from a thyroid disorder.¹ The clinical spectrum is wide but the most common presentation is thyroid swelling.^{2,3} Improvement in imaging techniques pick up small nonpalpable nodules in its incipient stage causing increase in the incidence.⁴

Periodic neck sonogram is ideal but does not happen, especially once the patient knows that the swelling is not malignant. Follow up surveillance with ultrasound and/or cytology for initially nodules is individualized based on sonographic features.⁵ In low-income countries, the

ultrasound (US) and computerized tomography (CT) of the thyroid are expensive, limiting the evaluation to the physical examination of thyroid abnormalities. Some of the previous methods of thyroid physical examination are still largely insensitive or non-specific with lack of evidence of their accuracy.

One grey zone of clinical examination of thyroid swelling is the palpability of the lower border which comes in handy for ruling out retrosternal goitre. A retrosternal goitre is defined when 50% of the mass is in the mediastinum.⁶ Ultrasonography cannot comment on the intrathoracic extension and fine needle aspiration cytology (FNAC) is not feasible. CT/magnetic resonance imaging (MRI) is required to rule it out. Due to the high cost of these imaging

modalities, patients need to be segregated into those who absolutely need them from those who do not.

The purpose of this study is to evaluate the diagnostic indices of different methods of physical examination and to comment on the inter-examiner variation in the physical findings of various clinical methods with training as compared to ultrasonography, which is the gold standard.

METHODOLOGY

This cross-sectional observational study was conducted at the Department of Surgery of a tertiary care University teaching hospital after ethical clearance. Patients with neck swellings over the front of the neck region moving with deglutition, who attended the outpatient Department of Surgery and Endocrinology, were enrolled after an informed consent was taken. Patients who had either received prior interventions (core needle, incisional biopsy, and surgical intervention) or refused for consent were excluded from study.

Sample size

Sample size for the study was computed to estimate sensitivity and specificity of lower border visibility of thyroid swelling based on the following assumptions: Both sensitivity and specificity of any of the four tests as 90%; absolute precision as 10% and 95% confidence level. We required thirty-five patients having visible lower boundaries and thirty-five patients with lower boundaries that are not visible. Assuming that in 50% of the patients with goiter, the lower boundaries would be visible, we needed to enroll seventy patients. However, considering potential missing values, we enrolled eighty-three patients in the study.

Details of clinical examination

Detailed examination of neck region in sitting and lying position was conducted in good light both from front and side of the neck. Inspection was followed by different methods of physical examination: Lahey's, Pizzilo's, and Crile's method and modified Rose method. Crile's method of examination was performed in patients having comparatively smaller swelling so only fifty-two patients were examined with this method by the consultant and fifty-six patients by the resident.

Examination in Modified Rose Method

Patient was asked to lie down. A pillow was placed below the shoulder blade with 10-12 cm elevation while extending the head and neck. A head support is placed behind the occiput of the patient (Figure 1). Patient's discomforts should be assessed at this stage for breathing difficulty, pain over the neck. Begin the examination as follows (Figure 2A-2H):

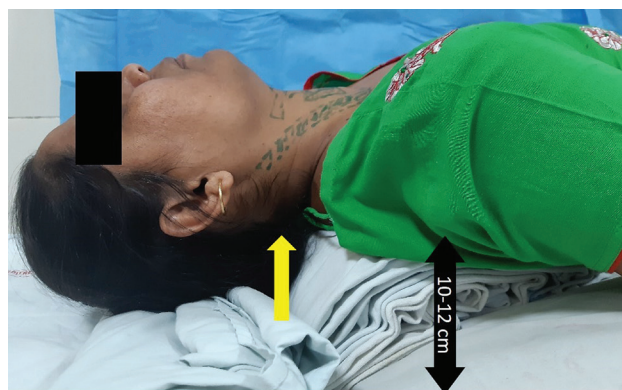

Figure 1. Positioning the patient for Modified Rose's Method. The yellow arrow shows the hyperextended neck, and the black double arrow shows the necessary elevation of shoulder blades should be 10-12 cm. This can be achieved by a shoulder roll or a pillow.

1. The palpation of swelling was performed with both hands to note any rise in temperature, tenderness, and consistency of the swelling(s). Any fixation to the skin and deep structure was also noted. Trachea, thyroid cartilage, cricoid cartilage was palpated to ascertain any deviation/compression of the airway.
2. First examine the isthmus part of the gland by placing examiner's thumb below the lower border of cricoid cartilage and over first two tracheal rings. Nodularity in its substance can be appreciated by gently holding it between thumb and the fingers.
3. To palpate the lateral lobes, the patient's chin should be turned slightly to the side intended to be examined, relaxing the SCM muscle on that side.
4. Palpation of the right lobe was done with the examiner's right hand, while pressing the opposite lobe towards midline by the left hand to make the right lobe more prominent.
5. Now the examiner gently insinuates the fingers of his palpating hand along the anterior border of the sternocleidomastoid muscle deep into the posterior surface of the thyroid gland, keeping the thumb over the lateral surface of the lower portion of the thyroid cartilage.
6. The examiner gently grasps the gland between his fingers and thumb to appreciate the surface, consistency, and presence of nodule(s). The patient is requested to swallow and the examiner assesses for mobility and defines the upper and lower margins of the gland (Figure 2F).
7. Caution should be exercised not to mistake the belly of the SCM as part of the thyroid gland (Figure 2H).
8. This method should be avoided in patients with any kind of cervical spine disease or with large goiter leading to tracheal instability signs (stridor, breathing distress).

Two investigators performed the physical examination independently. One investigator was a postgraduate resident, and another investigator was a faculty member

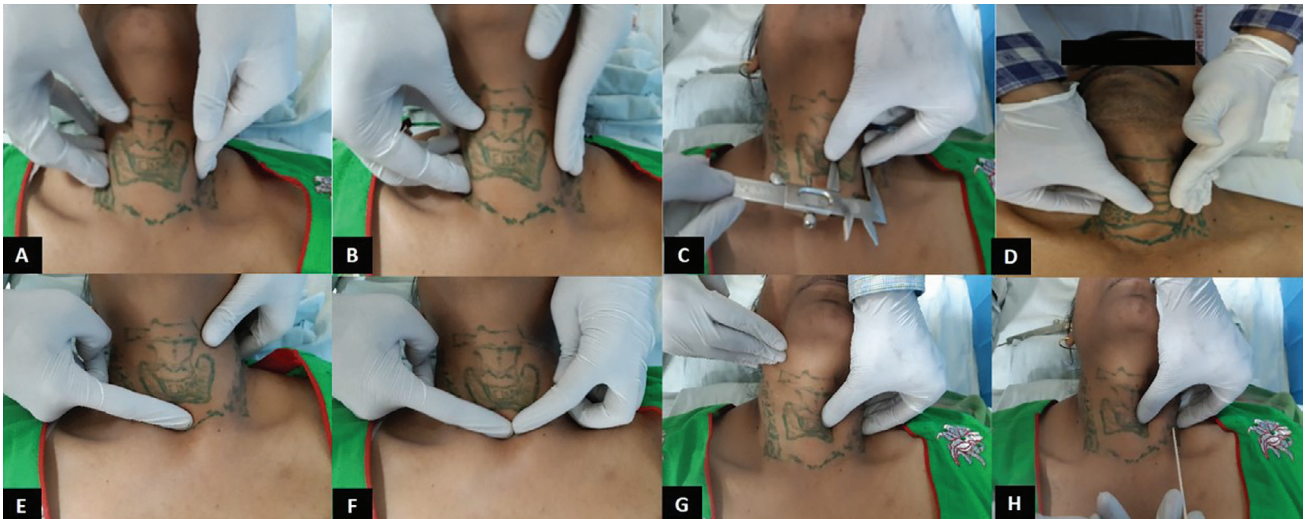


Figure 2. Examination by Modified Rose's method for a solitary thyroid nodule. (A) Head is turned to the side of palpation; (B) palpating the right lobe; (C) measurement by Vernier callipers; (D) palpating the left lobe; (E) palpating the lower border; (F) palpating the lower border on swallowing. Caution while palpating (G) thyroid gland, (H) sternocleidomastoid muscle may be mistaken as thyroid gland substance.

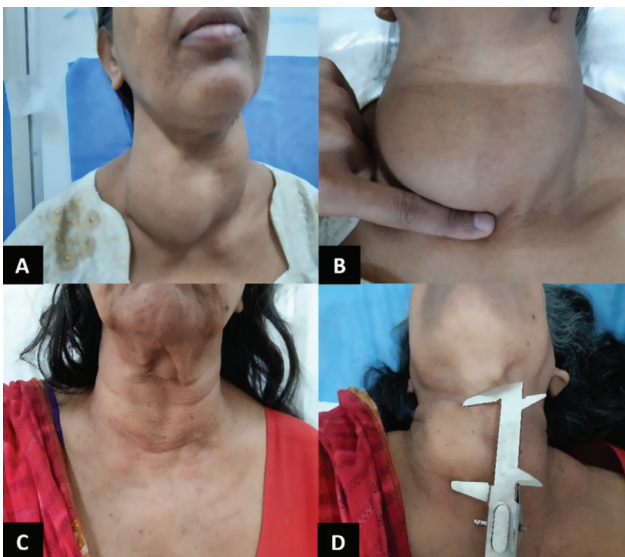

Figure 3. Examination by Modified Rose method. (A) A multinodular goitre seen on standing position; (B) examined in the modified rose position with palpation of the lower border; (C) faintly visible swelling on standing position; (D) the same swelling became prominent when examined in this position.

from the Department of Surgical Disciplines. Investigators recorded the finding without conferring with each other. The resident was trained by the Professor of Surgery in performing the various physical examination methods till Cohen's kappa statistics attained a value of '0.9.' This junior resident started the recordings of finding only after his training. The thyroid swellings were examined using four methods: Lahey's, Crile's, Prizzilo's and modified Rose (Appendix 1) in this sequence and the findings noted (Appendix 2). The duration of examination was somewhere between 10-15 minutes. Ultrasound (USG) of neck was performed in all the patients and considered

the gold standard for certain parameters. We computed different diagnostic indices for various parameters by different methods. We considered following parameters for thyroid examination: nodularity, consistency of nodule, palpability of lower border, size in cranio-caudal dimension and tracheal deviation. The presence of cervical lymphadenopathy was also noted. The agreement between clinical examination and ultrasound scan findings for different parameters was computed. For retrosternal extension, CT scan of the neck and thorax was considered the gold standard.

Statistical analysis

Data was analysed by Stata-14 and presented in Mean, Standard Deviation, and frequency percentages. Agreement between the two categorical variables was assessed by Kappa. In case of continuous variable agreement was assessed by ICC (intra class correlation) and Bland-Altman plot. Interpretation of Cohen's kappa values is, below 0 is no agreement, 0-0.2 is slight agreement, 0.21-0.40 as fair, 0.41-0.60 as moderate, 0.61-0.80 as substantial, and 0.81-1 as almost perfect agreement based on the guidelines by Landis and Koch.⁷ The sensitivity, specificity NPV, PPV with 95% CI was assessed for diagnostic methods in comparison to gold standard. The association between two categorical variables was tested using either Chi square test or Fischer's exact test.

RESULTS

A total of 83 patients with thyroid enlargements were enrolled for study. Majority of patients were females, 69 (83%) and remaining 14 (17%) were male patients. The predominant age group was 36-50 years in 31% patients followed by 26-35 years (29%). The chief complaint leading to consultation at the Surgery OPD was thyroid

enlargement (91.50%). Breathing difficulty was seen in 18 (21.70%) patients. Thirteen (15.60%) patients presented with voice changes. Difficulty in swallowing was seen in 14 (16.87%) patients. No patient had history of radiation exposure. There were 7 incidentally detected thyroid nodule cases (8.4%, 4 picked up on CT on 3 on USG).

Agreement for nodularity

The USG examination revealed that 1 (1.20%) patient had a normal thyroid gland, 2 (2.41%) patients had a non-thyroidal swelling, 38 (45.78%) patients had a STN, and 42 (50.60%) patients had presented with an multinodular goitre (MNG). Modified Rose method showed 93.98% (kappa = 0.91, excellent agreement in identification of nodule in thyroid swelling followed by Crile’s method 86.54% (kappa = 0.79), Pizzilo’s method 81.93% (kappa = 0.75) and Lahey’s method 80.72% (kappa = 0.73). The agreement for the resident was good using modified Rose and moderate in others (Table 1). All these agreements were statistically significant.

Agreement for consistency of nodule

Modified Rose method when performed by the consultant and resident showed fair agreement at 59.50% and 37% respectively (kappa = 0.40), to identify consistency of nodule. Crile’s method showed least agreement 17% and 19% respectively (kappa = 0.079). These are depicted in Table 1. All agreements were statistically significant.

Agreement for finding lymph nodes

Lahey’s and Pizzilo’s method showed better agreement at 90.36% in both (kappa = 0.58 each) followed by Crile’s method at 88.46% (kappa = 0.55). Least agreement was seen with modified Rose method at 87.95% with kappa of 0.5 (when performed by a consultant). When this was done by a resident, Lahey’s method showed highest agreement at 92.77% (kappa = 0.70) followed by modified Rose method at 90.36% (kappa = 0.61). These findings were statistically significant. Therefore, it was interpreted that Lahey’s method was the best clinical method among the four to palpate lymph nodes (Table 1).

Mean of vertical dimension

The mean of vertical dimension measured by a consultant in the modified Rose method was comparatively higher than in other methods as shown by the difference of means in Table 2. Mean differences measured between Lahey’s vs modified Rose/ Pizzilo’s vs modified Rose/ Crile’s vs modified Rose were all in negative value with an excellent ICC value (>0.9). It is consistent with the logic that in the modified Rose position, due to greater neck extension, some occult part of the substernal goiter comes out and becomes palpable. Similar results were reflected when measured by resident.

Bland Altman Plot for dimensions

The Bland Altman Plot was drawn for agreement between craniocaudal dimension of enlarged lobe measured by Lahey’s method and modified Rose method. Most of the measurements lies within 95% limits of agreement. There were only 4 out of 59 (6.78%) outside the limit of agreement (Figure 4A). The 95% confidence interval varies from -1.7 cm to 0.8 cm which is slightly larger than the pre-set value of plus minus 1 cm. The values outside the agreement range were within the acceptable limit of 10%. Modified Rose method measures the size more accurately as compared to Lahey’s method. The other Bland Altman plot was drawn for agreement between craniocaudal dimension of the enlarged lobe measured by Pizzilo’s method versus modified Rose method. The confidence interval varies from -1.4 cm to 0.9 cm which is slightly larger than the expected interval but narrower than the interval between the previous comparison. The values outside the agreement were acceptable at 4 out of 59 (6.78%) (Figure 4B).The mean of the difference of craniocaudal measurements by the two methods was 0.43 cm between Lahey’s and Rose as compared to a narrower difference between Pizzilo and Rose at 0.25 cm. Another trend noted was that as the size of the nodule increased and the more inferior is the location of the lower border, the greater is the discrepancy. This could be explained by the non-palpability of the lower border. Thus, to measure the craniocaudal dimension the most accurate method is modified Rose followed by Pizillo and Lahey’s respectively.

Table 1. Agreement for various parameters between USG and clinical methods; Consultant (C) and Resident (R)

Parameter Assessed		Lahey’s (n=83)		Pizzilo’s (n=83)		Crile’s (n=52 C & n=56 R)		Modified Rose (n=83)	
		C	R	C	R	C	R	C	R
Nodularity	Agreement %	80.72%	77.10%	81.93%	78.31%	86.54%	83.98%	93.98%	86.75%
	Cohen’s Kappa (95% CI)	0.73 (0.60-0.85)	0.68 (0.56-0.79)	0.75 (0.63-0.87)	0.70 (0.57-0.82)	0.79 (0.62-0.95)	0.76 (0.60-0.91)	0.91 (0.78-1.03)	0.81 (0.68-0.93)
	P value	<0.001	<0.001	<0.001	<0.001	<0.001	<0.001	<0.001	<0.001
Consistency	Agreement %	26.90%	44.30%	26%	40%	17%	19%	59.50%	37%
	Cohen’s Kappa (95% CI)	0.20 (0.10-0.30)	0.23 (0.12-0.34)	0.21 (0.11-0.31)	0.20 (0.10-0.30)	0.08 (0.02-0.18)	0.11 (0.01-0.21)	0.40 (0.20-0.57)	0.49 (0.36-0.62)
	P value	<0.001	<0.001	<0.001	<0.001	0.05	0.01	<0.001	<0.001
Lymph Node palpability	Agreement %	90.36%	92.77%	90.36%	90.30%	88.46%	90.09%	87.95%	90.36%
	Cohen’s Kappa (95% CI)	0.58 (0.43-0.73)	0.70 (0.55-0.84)	0.58 (0.43-0.73)	0.58 (0.43-0.72)	0.55 (0.35-0.74)	0.58 (0.39-0.76)	0.50 (0.35-0.65)	0.61 (0.45-0.74)
	P value	<0.001	<0.001	<0.001	<0.001	<0.001	<0.001	<0.001	<0.001

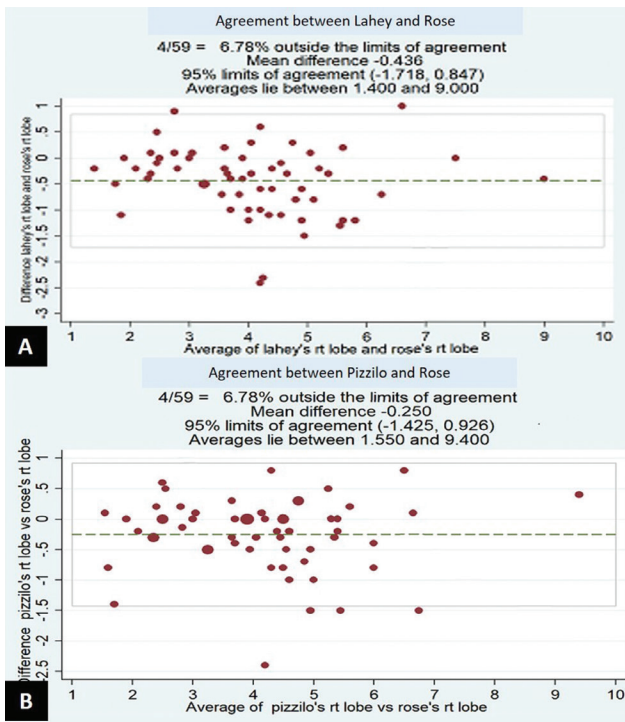


Figure 4. Bland-Altman plot for agreement between craniocaudal dimension measured by the consultant using the (A) Lahey's method vs Modified Rose's method; (B) Pizzilo's method and Modified Rose's method.

Diagnostic test indices for finding Solitary Thyroid Nodule (STN) and multinodular goitre (MNG)

The sensitivity to identify STN was seen highest (Consultant – 97%, Resident – 100%) with Crile's method but specificity was low (Consultant – 75%, Resident – 70%). Modified Rose method had high sensitivity and specificity for the Consultant at 94% and 100% compared to that of Resident at 86.80% and 95.50%, respectively. Lahey's and Pizzilo's method were moderately sensitive and specific (Table 3). The sensitivity to identify multinodular goitre (MNG) by modified Rose method was high (Consultant – 100%, Resident – 86%). The other 3 methods were moderately sensitive. The specificity of all methods to identify MNG was good (Table 4). The agreement of modified Rose was highest, excellent with consultant examination.

Diagnostic test indices for palpability of lower border

It was observed that modified Rose method by consultant has the highest sensitivity (98%) and diagnostic odds (210) as compared to other conventional methods of thyroid examination but its specificity ranges from 46.7 to 91.1 (75%). A CT of the neck and thorax was taken as the gold standard to rule out retrosternal extension. The level of agreement for modified Rose is good as compared to fair agreement by all other methods (Table 5).

Table 2. Mean difference of size (vertical dimension) by various methods and intraclass correlation by consultant and resident

Cranio-caudal Dimensions (Mean±SD cm)	Consultant		Resident	
	Right Lobe (n=66)	Left Lobe (n=47)	Right Lobe (n=66)	Left Lobe (n=47)
Lahey's	3.82±1.42	3.45±1.78	4.01±1.84	3.53±1.89
Pizzilo's	3.9±1.48	3.66±1.75	4.1±1.89	3.73±1.77
Crile's	3.75±1.32 (n=34)	3.66±1.85 (n=18)	3.54±1.41 (n=36)	3.73±2.05 (n=26)
Modified Rose	4.31±1.76	3.74±1.78	4.47±2.0	3.95±1.96
Lahey-Rose	Difference of mean (95% CI) -0.46 (-0.69, -0.24) -0.51 (-0.80, -0.23) -0.46 (-0.69, -0.24) -0.61 (-0.92, -0.31)			
	ICC 0.94 0.95 0.94 0.93			
Pizzilo-Rose	Difference of mean (95% CI) -0.24 (-0.40, -0.09) -0.32 (-0.54, -0.11) -0.29 (-0.49, -0.08) -0.41 (-0.62, -0.19)			
	ICC 0.96 0.96 0.94 0.95			
Crile-Rose	Difference of mean (95% CI) -0.25 (-0.39, -0.10) -0.22 (-0.46, 0.02) -0.27 (-0.54, 0.01) -0.33 (-0.55, -0.11)			
	ICC 0.96 0.98 0.91 0.97			

Table 3. Diagnostic test indices for finding Solitary Thyroid Nodule (STN) with USG as a gold standard for Consultant (C) and Resident (R)

STN	Lahey's (n=83)		Pizzilo's (n=83)		Crile's (n=52 C & n=56 R)		Modified Rose (n=83)	
	C	R	C	R	C	R	C	R
Sensitivity (95% CI)	94% (82.70-98.50)	92.10% (79.20-97.20)	94% (82.70-98.54)	94.70% (82.70-98.50)	97% (85.80-99.50)	100% (90.30-100)	94% (82.70-98.50)	86.80% (72.60-94.20)
Specificity (95% CI)	84% (71.20-92.20)	82.20 (68.70-90.70)	86% (73.80-93.70)	80% (66.10-89.10)	75% (50.50-89.80)	70% (48-85.45)	100% (92.10-100)	95.50% (85.10-98.70)
PPV (95% CI)	83% (70-91.80)	81.40% (67.30-90.20)	85% (72.10-93.20)	80% (66.10-89.10)	89% (76.40-95.90)	85.7% (72.10-93.20)	100% (90.30-100)	94.20% (81.30-98.40)
NPV (95% CI)	95% (83.50-98.60)	92.50% (80.14-97.42)	95% (83.80-98.60)	94.70% (82.70-98.50)	92% (66.60-98.60)	100% (78.40-100)	95% (85.70-98.80)	89.50% (77.80-95.40)
Diagnostic Accuracy (95% CI)	89% (80.60-94.10)	86.70% (77.80-92.40)	90% (82.10-95)	86.70% (77.80-92.40)	90% (79.30-95.80)	89.2% (78.50-95)	97% (91.60-99.30)	91.50% (83.60-95.80)
Diagnostic Odds (95% CI)	97 (19-501)	53.9 (13.20-219.90)	117 (22-617)	72 (14.50-365)	105 (10.60-1034)	Not defined	Not defined	141 (25.80-777)
Cohen's kappa (95% CI)	0.78 (0.57-0.99)	0.73 (0.52-0.94)	0.80 (0.59-1.00)	0.73 (0.52-0.94)	0.76 (0.49-1.00)	0.75 (0.49-1.00)	0.95 (0.73-1.00)	0.82 (0.61-1.00)
P value	<0.0001	<0.0001	<0.0001	<0.0001	<0.0001	<0.0001	<0.0001	<0.0001

Table 4. Diagnostic test indices for finding Multinodular Goitre (MNG) with USG as a gold standard for Consultant (C) and Resident (R)

MNG	Lahey's (n=83)		Pizzilo's (n=83)		Crile's (n=52 C & n=56 R)		Modified Rose (n=83)	
	C	R	C	R	C	R	C	R
Sensitivity (95% CI)	66% (49.60-80.20)	60.60% (43.60-75.30)	69% (52.60-82.60)	60.60% (43.60-75.30)	66% (39-86.10)	56.20% (33.10-76.90)	100% (89.50-100)	90.90% (76.40-96.80)
Specificity (95% CI)	100% (92.80-100)	98% (89.50-99.60)	100% (92.80-100)	96% (86.50-98.90)	97% (87.10-99.50)	100% (91.80-100%)	96% (86.50-98.90)	94% (83.70-97.90)
PPV (95% CI)	100% (85.10-100)	95.20% (77.30-99.10)	100% (85.60-100)	90.90% (72.10-97.40)	88% (56.50-90)	100% (70-100)	94% (81.30-98.40)	90.90% (76.40-96.80)
NPV (95% CI)	81% (70.50-89.60)	79% (67.30-87.30)	83% (71.90-90.60)	78.60% (66.80-87.10)	90% (79.30-95.80)	86% (73.80-93)	100% (92.50-100)	94% (83.70-97.90)
Diagnostic Accuracy (95% CI)	86% (77.80-92.40)	83.10% (73.60-89.60)	87% (79.20-93.30)	81.90% (72.30-88.70)	90% (79.30-95.82)	88.10% (77.40-94.10)	97% (91.60-99.30)	92.70% (85.10-96.60)
Diagnostic Odds (95% CI)	Not defined	75.30% (9.20-615)	Not defined	36.90 (7.60-178)	78 (7.60-793)	Not defined	Not defined	156 (29.60-827)
Cohen's kappa (95% CI)	0.70 (0.50-0.91)	0.62 (0.42-0.82)	0.73 (0.52-0.94)	0.60 (0.39-0.80)	0.70 (0.43-0.97)	0.65 (0.41-0.89)	0.95 (0.73-1.00)	0.84 (0.63-1.00)
P value	<0.0001	<0.0001	<0.0001	<0.0001	<0.0001	<0.0001	<0.0001	<0.0001

Table 5. Diagnostic test indices for palpability of lower border with CT as gold standard for Consultant (C) and Resident (R)

Lower Border	Lahey's (n=83)		Pizzilo's (n=83)		Crile's (n=52 C & n=56 R)		Modified Rose (n=83)	
	C	R	C	R	C	R	C	R
Sensitivity (95% CI)	77% (66.40-85.60)	76% (64.90-84.80)	87% (77.60-93.20)	85% (75.90-92.00)	77% (63.40-86.60)	82% (69.20-90.20)	98% (92.40-99.70)	98% (92.40-99.70)
Specificity (95% CI)	83% (55.20-95.30)	83% (55.20-95.30)	58% (31.90-80.60)	75% (46.70-91.10)	75% (30.06-95.44)	80% (37.50-96.30)	75% (46.70-91.10)	66% (39.00-86.19)
PPV (95% CI)	38% (22.40-57.40)	37% (21.50-55.70)	43% (23.10-66.80)	47% (27.30-68.20)	21% (7.57-47.50)	30% (12.60-57.60)	90% (59.50-98.20)	88% (56.50-98.10)
NPV (95% CI)	96% (88-99.30)	96% (87.80-99)	92% (83.60-96.70)	95% (87.10-98.30)	97% (86.50-99.50)	97% (87.60-99.50)	95% (88.26-98.10)	94% (86.90-97.80)
LR+ (95% CI)	4.64 (1.73-12.50)	4.50 (1.69-12.30)	2.09 (1.41-3.11)	3.40 (1.70- 6.66)	3.08 (0.43- 22.24)	4.10 (0.57-29.4)	3.94 (2.05-7.50)	2.95 (1.81-4.83)
LR- (95% CI)	0.27 (0.23-0.32)	0.28 (0.24-0.35)	0.21 (0.19-0.24)	0.18 (0.14-0.24)	0.30 (0.21-0.45)	0.22 (0.16-0.31)	0.02 (0.01-0.14)	0.02 (0.01-0.17)
Diagnostic odds (95% CI)	17 (3.41-86.60)	15 (3.16-79.70)	9 (2.52-36.90)	18 (4.20-79.40)	10 (0.95-107)	18 (1.81- 183)	210 (19.6- 2240)	140 (13.90-1411)
Diagnostic Accuracy (95% CI)	78% (68.30-85.60)	77% (66.90-84.80)	83% (73.60-89.60)	84% (74.10-90.40)	76% (63.8-86.28)	81% (72.80-87.20)	95% (88.20-98.10)	95% (88.20-98.10)
Cohen's Kappa (95% CI)	0.41 (0.22-0.60)	0.39 (0.20-0.58)	0.40 (0.19-0.61)	0.49 (0.28-0.69)	0.24 (0.03-0.45)	0.36 (0.13-0.58)	0.79 (0.57-1.00)	0.72 (0.52-0.94)
P value	<0.0001	<0.0001	<0.0001	<0.0001	<0.0001	<0.0001	<0.0001	<0.0001

Association between sub-sternal extension by clinical methods and Pemberton's sign

If Pemberton's sign positive, physical examination by Lahey's, Pizzilo's and modified Rose method shows probability of substernal extension in 78%, 56% and 78% respectively, when examined by the Consultant. With a negative Pemberton's sign, the probability of getting false positive finding of substernal extension was 26%, 15% and 4% respectively. When examined by the Resident, there was lower probability of getting false positive finding with modified Rose method (p-value <0.001).

DISCUSSION

The thyroid gland weighs 10-20 grams in a normal adult, is not usually palpable in health due to its relatively soft consistency and the coverage provided by the strap muscles. There are very few studies in the literature describing the appropriate physical examination of thyroid region swelling. With the improvement in techniques of

imaging, the importance of thyroid examination has been overshadowed by unreasonable reliance on these modalities. A narrow differential diagnosis can be established by a simple physical examination of the thyroid gland by an experienced clinician.⁸ The evaluation of thyroid swelling must begin with a proper clinical examination followed by imaging and cytology studies. Many methods have been described in literature for examination of thyroid swellings like Lahey's, Pizzilo's and Crile's methods.⁹

Thorough characterization of the interobserver variation on ultrasound of the thyroid is important. Knudsen et al., studied the interobserver variation of the ultrasound examination of thyroid in 25 patients.¹⁰ They compared findings of postmortem ultrasonography of the thyroid with finding after autopsy. Echogenicity and echo pattern showed less agreement but good correlation and agreement between observers was found for thyroid volume (r = 0.98) and prevalence of thyroid nodules (kappa = 0.72). The correlation of thyroid volume by ultrasonography to autopsy results was satisfactory (r = 0.93), but the

volume was slightly underestimated.¹¹⁻¹³ The ACR TI-RADS (Thyroid Imaging Reporting and Data System) assess thyroid nodules under 5 categories: composition, echogenicity, shape, margin and echogenic foci; and based on total combine score assign a risk level that ranges from TR1 to TR5. The risk of malignancy is TR1 (0.3%), TR2 (1.5%), TR3 (4.8%), TR4 (9.1%), TR5 (35%).¹⁴ The goal of this surveillance is detecting the missed thyroid malignancies on the initial assessment.¹⁵

Lahey's method was described by Frank H Lahey in 1926. It gives information about the anterior surface of the thyroid nodule and increases the prominence of lateral lobes, thus highlighting the small nodules.⁹ It also allows for assessment of the consistency of the nodule. Contrary to this, our study highlighted that Lahey's method had the least agreement for assessing the nodularity, consistency and cranio-caudal dimensions but had the highest agreement for the lymph node assessment. The sensitivity of Lahey's method to identify a solitary nodule was comparable to the other three methods. The sensitivity to identify multinodular goiter and the palpability of the lower border was the lowest among these four methods.

Pizzillo's method was described to facilitate the examination of the thyroid region in obese individuals with short neck. The neck is extended to better appreciate the nodules. Our study revealed that the agreement levels were comparable for assessing the nodularity and lymph node status but poor for consistency. It was almost as accurate as the Rose method to measure the cranio-caudal dimension of the nodule. The sensitivity to identify the solitary nodule was comparable to the others, however, the sensitivity for multinodular goiter was very low. The sensitivity to palpate the lower border was higher than all the other methods except the Rose method. This was primarily because of the extension of the neck which was not done in the Lahey's and Crile's method.

Crile's method was described for palpation of smaller nodules. This was confirmed by our study by the high sensitivity to identify the solitary nodule and the lowest sensitivity for multinodular goiter and palpation of the lower border. The agreement to measure the nodularity and lymph nodes was high, but it was poorest for the consistency.

In the classic Rose position described by Professor Edmund Rose, Trendelenburg position was recommended.¹⁶ This was proposed for the patients undergoing head and neck surgeries and the position was achieved on the operation theatre table. But to practice this clinically in the out-patient as well as the ward setup, modification was needed. So, the modified Rose position was devised, in which the patient lies flat with elevation of shoulder blades with a pillow and extension at the neck joints. This is feasible in the examination rooms where the modular operating tables (OT) tables are not encountered routinely. The anatomic advantages offered by this position is because the neck

extension causes the laryngo-pharyngeal unit to be pulled cranially towards the skull base. This makes the swelling more discernable for palpation. This also allows for the palpation of the lower border of the swelling which in sitting position dips behind the sterno-clavicular joint and the clavicle. Our study confirmed that the agreement for nodularity, consistency and the cranio-caudal dimension was highest with this method. The agreement for lymph nodes was second to the Lahey's method. This is the most sensitive method to identify the solitary nodule, multinodular goiter and the palpation of the lower border of the swelling. It also has the highest specificity, positive likelihood ratio and the best diagnostic odds for these characteristics. Thus, modified Rose emerges as the single best method to assess all the features of the thyroid enlargement for a superior diagnostic yield.

The palpability of the lower border of thyroid sounds less important but has a great bearing to the evaluation. As per various textbooks a retrosternal goitre is one that has 50% of the mass in the mediastinum. Ultrasonography cannot comment on the intrathoracic part and FNAC is not feasible. So, for diagnosis of retrosternal extension, CT/MRI is required.¹⁷ So, for a resource limited setting like ours, a clinical method should be devised which can guide the necessity to do CT to rule out the extension.

We found in our study that the new method "Modified Rose's Method" has the highest sensitivity and diagnostic odds as compared to other conventional methods of thyroid examination, but its specificity is moderate. Hence, the modified Rose technique and its findings should guide decision making in performing USG and CT as well. It is expected that use of this method would clearly prioritise those patients who need CT for further assessment, optimising the use of limited resource in low-middle income class countries.

This is the first study in literature which has compared 4 different methods of clinical examination of thyroid enlargement. It was found that modified Rose's method has high sensitivity and specificity to identify solitary thyroid nodule when compared to neck ultrasound as gold standard. The sensitivity to identify multinodular goiter was also high. The other advantages of this method were that inspection, palpation and auscultation could be performed in one position. So, it was time saving especially in the busy environment of the Out-Patient Clinic (OPD).

A major disadvantage of this method is its inapplicability to be used in patient with exceptionally large goiter (stridor, breathing distress) and patients with cervical spine disease (trauma, instability, disc prolapse). Lahey's method is a relatively better clinical method to palpate lymph nodes. Perhaps it is the extension causes the bilateral sternocleidomastoid (SCM) muscles to be taut. It would be difficult to palpate cervical lymph nodes when the SCM is less relaxed.

Another interesting trend highlighted throughout the study is that the diagnostic indices of the Consultant were superior to those of the Resident in almost all the scenarios. This is an expected finding as clinical examination improves by experience.

Strengths

This is the first study available in English literature to have compared all methods of clinical thyroid examination in living human patients. The study consistently shows modified Rose's method was superior to others. The study also emphasizes the importance of thoroughness in clinical examination of thyroid. The study also demonstrates reproducibility of the results as performed by two different examiners with varying level of experience.

Limitations

The study was done at a single centre with limited number of patients. As the study was done for a limited period, a strict inclusion criterion could not be followed, and a sample of convenience was taken. The number of patients examined by all the methods were not equal due to the size differences of the goiters.

CONCLUSION

Modified Rose's position is the best method of clinical examination of thyroid swellings especially in patients with occult substernal extension. Lahey's method is better for the examination of cervical lymph nodes. Considering the better diagnostic indices that we got in our patients, this method can be used in field studies to screen thyroid swelling in at-risk population.

Statement of Authorship

All authors certified fulfillment of ICMJE authorship criteria.

Author Disclosure

The authors declared no conflict of interest.

Funding Source

None.

References

- Unnikrishnan AG, Menon UV. Thyroid disorders in India: An epidemiological perspective. *Indian J Endocrinol Metab.* 2011;15 (Suppl 2):S78-81. PMID: 21966658. PMCID: PMC3169866. <https://doi.org/10.4103/2230-8210.83329>.
- Guerra G, Cinelli M, Mesolella M, et al. Morphological, diagnostic and surgical features of ectopic thyroid gland: A review of literature. *Int J Surg.* 2014;12 Suppl 1:S3-11. PMID: 24887357. <https://doi.org/10.1016/j.ijsu.2014.05.076>.
- Noussios G, Anagnostis P, Goulis DG, Lappas D, Natsis K. Ectopic thyroid tissue: Anatomical, clinical, and surgical implications of a rare entity. *Eur J Endocrinol.* 2011;165(3):375-82. PMID: 21715415. <https://doi.org/10.1530/EJE-11-0461>.
- Chung WY, Chang HS, Kim EK, Park CS. Ultrasonographic mass screening for thyroid carcinoma: A study in women scheduled to undergo a breast examination. *Surg Today.* 2001;31(9):763-7. PMID: 11686552. <https://doi.org/10.1007/s005950170044>.
- Cappola AR, Mandel SJ. Improving the long-term management of benign thyroid nodules. *JAMA.* 2015;313(9):903-4. PMID: 25734731. <https://doi.org/10.1001/jama.2015.0836>.
- Rugiu M, Piemonte M. Surgical approach to retrosternal goitre: Do we still need sternotomy? *Acta Otorhinolaryngol Ital.* 2009;29(6):331-8. PMID: 20463839. PMCID: PMC2868211.
- Landis JR, Koch GG. The measurement of observer agreement for categorical data. *Biometrics.* 1977;33(1):159-74. PMID: 843571.
- Walker HK, Hall WD, Hurst JW, eds. *Clinical methods: The history, physical, and laboratory examinations*, 3rd ed. Boston: Butterworths; 1990.
- Lahey FH. A method of palpating the lobes of the thyroid. *JAMA.* 1926;86(12):813-4. <https://doi.org/10.1001/jama.1926.02670380003002>
- Knudsen N, Bols B, Bülow I, et al. Validation of ultrasonography of the thyroid gland for epidemiological purposes. *Thyroid.* 1999;9(11):1069-74. PMID: 10595454. <https://doi.org/10.1089/thy.1999.9.1069>.
- Marqusee E, Benson CB, Frates MC, et al. Usefulness of ultrasonography in the management of nodular thyroid disease. *Ann Intern Med.* 2000;133(9):696-700. PMID: 11074902. <https://doi.org/10.7326/0003-4819-133-9-200011070-00011>.
- Tan GH, Gharib H, Reading CC. Solitary thyroid nodule. Comparison between palpation and ultrasonography. *Arch Intern Med.* 1995;155(22):2418-23. PMID: 7503600. <https://doi.org/10.1001/archinte.155.22.2418>.
- Schneider AB, Bekerman C, Leland J, et al. Thyroid nodules in the follow-up of irradiated individuals: Comparison of thyroid ultrasound with scanning and palpation. *J Clin Endocrinol Metab.* 1997;82(12):4020-7. PMID: 9398706. <https://doi.org/10.1210/jcem.82.12.4428>.
- Middleton WD, Teehey SA, Reading CC, et al. Multiinstitutional analysis of thyroid nodule risk stratification using the American College of Radiology Thyroid Imaging Reporting and Data System. *AJR Am J Roentgenol.* 2017;208(6):1331-41. PMID: 28402167. <https://doi.org/10.2214/AJR.16.17613>.
- Durante C, Costante G, Lucisano G, et al. The natural history of benign thyroid nodules. *JAMA.* 2015;313(9):926-35. PMID: 25734734. <https://doi.org/10.1001/jama.2015.0956>.
- Bickham WS. Misconception, in America, as to the Rose position. *JAMA.* 1931;96(26):2185-7. <https://doi.org/10.1001/jama.1931.02720520013004>
- Haugen BR, Alexander EK, Bible KC, et al. 2015 American Thyroid Association Management guidelines for adult patients with thyroid nodules and differentiated thyroid cancer: The American Thyroid Association Guidelines Task Force on thyroid nodules and differentiated thyroid cancer. *Thyroid.* 2016;26(1):1-133. PMID: 26462967. PMCID: PMC4739132. <https://doi.org/10.1089/thy.2015.0020>.

Authors are required to accomplish, sign and submit scanned copies of the JAFES Author Form consisting of: (1) Authorship Certification, that authors contributed substantially to the work, that the manuscript has been read and approved by all authors, and that the requirements for authorship have been met by each author; (2) the Author Declaration, that the article represents original material that is not being considered for publication or has not been published or accepted for publication elsewhere, that the article does not infringe or violate any copyrights or intellectual property rights, and that no references have been made to predatory/suspected predatory journals; (3) the Author Contribution Disclosure, which lists the specific contributions of authors; (4) the Author Publishing Agreement which retains author copyright, grants publishing and distribution rights to JAFES, and allows JAFES to apply and enforce an Attribution-Non-Commercial Creative Commons user license; and (5) the Conversion to Visual Abstracts (*optional for original articles only) to improve dissemination to practitioners and lay readers. Authors are also required to accomplish, sign, and submit the signed ICMJE form for Disclosure of Potential Conflicts of Interest. For original articles, authors are required to submit a scanned copy of the Ethics Review Approval of their research as well as registration in trial registries as appropriate. For manuscripts reporting data from studies involving animals, authors are required to submit a scanned copy of the Institutional Animal Care and Use Committee approval. For Case Reports or Series, and Images in Endocrinology, consent forms, are required for the publication of information about patients; otherwise, appropriate ethical clearance has been obtained from the institutional review board. Articles and any other material published in the JAFES represent the work of the author(s) and should not be construed to reflect the opinions of the Editors or the Publisher.

APPENDICES

Appendix 1. Standard steps of examination followed in the study

Lahey's method⁹

1. Patient is examined in the sitting position with the examiner in front of the patient.
2. Elevate the patient's chin ensuring the movement of patient's larynx and trachea forward. This maneuver increases the prominence of the lateral lobes.
3. With the neck in forward position, the chin is rotated slightly towards the side on which the lobe of the thyroid to be palpated, relaxing the ipsilateral sternocleidomastoid.
4. Then using the pulp of the thumb against the lower lateral portion of the thyroid cartilage and upper two rings of trachea. The trachea is to be dislocated laterally with gentle pressure from opposite site as far as possible without causing choking.
5. Then using the fingers of the opposite hand press deeply inward behind the sternomastoid and behind the thyroid lobe, and the thumb of that hand is brought over the anterior surface of the gland anterior to the sternomastoid. The dislocated lobe may then be palpated between the two.
6. Patient is asked to swallow to confirm the palpated structure is thyroid.

Pizzilo's method

1. Patient is examined in the sitting position with the head resting on the clasped hands at the occiput. The patient is asked to push the head backwards.
2. The examiner stands behind the patient to examine the gland.
3. With the pulp of the index, middle and ring finger the lobes of the gland are palpated on both the sides followed by palpation of the isthmus. The flexion should be at the metacarpophalangeal joint and should not poke the patient.
4. The patient is then asked to swallow to assess the lower border of the swelling as well as the retrosternal extension.
5. This method is usually employed for examining obese patients with shorter neck as neck extension ensures better access to the thyroid gland.

Crile's method

1. The patient is examined in the sitting position with head in normal position. The examiner stands in front of the patient. This method was described for small solitary thyroid swellings.
2. Pulp of the thumb of the examiner is used to palpate the gland for any abnormality. The examiner uses his/her left thumb to palpate the left side of the gland and vice versa.
3. The isthmus can be palpated with either hand of the examiner.
4. Patient is asked to swallow to visualise the lower border and rule out retrosternal extension

Modified Rose method

-Described in the main text-

Appendix 2. Case Record Form

Participant Identification Number:
 Name: Age: Gender: ... M / F ...
 UHID No.: Unit: Ward: Bed:
 Address: Phone No:

HISTORY:

<i>Symptoms</i>	<i>Duration</i>	<i>History of any hyperthyroidism symptoms</i>	<i>Duration</i>
• Thyroid Swelling (Self detection, physician)	Yes/No	• Insomnia	Yes/No
• Palpable cervical lymph nodes	Yes/No	• Diarrhoea	Yes/No
• Dysphagia	Yes/No	• Palpitations	Yes/No
• Dysphonia	Yes/No	• Heat intolerance	Yes/No
• Dyspnoea	Yes/No	• Sweating	Yes/No
• Pain	Yes/No	• Nervousness	Yes/No
• Others	Yes/No	• Tremors	Yes/No
• History of any radiation exposure in past	Yes/No	• Vision changes	Yes/No
• History of thyroid malignancy in family	Yes/No	• Hair loss	Yes/No

History of any hypothyroidism symptoms

• Fatigue and lethargy	Yes/No
• Muscular weakness	Yes/No
• Weight gain	Yes/No
• Constipation	Yes/No
• Voice changes	Yes/No
• Myxoedema	Yes/No
• Cold intolerance	Yes/No

CLINICAL EXAMINATION:

(S. No.) Methods

(1) Lahey’s method

- Right lobe enlargement
- Left lobe enlargement
- Diffuse enlargement
- Cervical Lymph node Enlargement
- Retrosternal Extension
- Tracheal Shift
- Stridor on compression
- Engorged neck veins
- Size (by Vernier calliper) –
- Consistency – Soft/Firm/Hard
- Mobility – Mobile/Restricted/Fixed

Findings

- Yes/No
- Yes/No
- Yes/No
- Yes/No
- Yes/No
- Yes/No
- Yes/No
- Yes/No

(2) Pizzilo’s method

- Right lobe enlargement
- Left lobe enlargement
- Diffuse enlargement
- Cervical Lymph node Enlargement
- Retrosternal Extension
- Tracheal Shift
- Stridor on compression
- Engorged neck veins
- Size (by Vernier calliper) –
- Consistency – Soft/Firm/Hard
- Mobility – Mobile/Restricted/Fixed

- Yes/No
- Yes/No
- Yes/No
- Yes/No
- Yes/No
- Yes/No
- Yes/No
- Yes/No

(3) Crile’s method

- Right lobe enlargement
- Left lobe enlargement
- Diffuse enlargement
- Cervical Lymph node Enlargement
- Retrosternal Extension
- Tracheal Shift
- Stridor on compression
- Engorged neck veins
- Size (by Vernier calliper) –
- Consistency – Soft/Firm/Hard
- Mobility – Mobile/Restricted/Fixed

- Yes/No
- Yes/No
- Yes/No
- Yes/No
- Yes/No
- Yes/No
- Yes/No
- Yes/No

(4) Modified Rose method

- Right lobe enlargement
- Left lobe enlargement
- Diffuse enlargement
- Cervical Lymph node Enlargement
- Retrosternal Extension
- Tracheal Shift
- Stridor on compression
- Engorged neck veins
- Size (by Vernier calliper) –
- Consistency – Soft/Firm/Hard
- Mobility – Mobile/Restricted/Fixed

- Yes/No
- Yes/No
- Yes/No
- Yes/No
- Yes/No
- Yes/No
- Yes/No
- Yes/No

INVESTIGATIONS:

S. Calcium

- o Value (mg/dL. mEq/dL)
- o Total/Ionized
- o Serum Phosphate:
- o Serum Albumin:

Thyroid Function Test

- o Free T3
- o Free T4
- o TSH

USG thyroid

- o Right lobe
- o Left lobe
- Size of Tumour cm side Left/Right
- o Cervical Lymph nodes:
 - Ipsilateral II/III/IV/V/V/VI
 - Contralateral II/III/IV/V/V/VI

NCCT thyroid

- o Right lobe
- o Left lobe
- Size of Tumour cm side Left/Right
- o Cervical Lymph nodes:
 - Ipsilateral II/III/IV/V/V/VI
 - Contralateral II/III/IV/V/V/VI

Retrosternal extension

FNAC

- o Accession No. & Date
- o Report:
- o Bethesda Category

Operative Findings