

## Atypical Eruptive Xanthoma: A Condition Confused With Monkeypox Rash

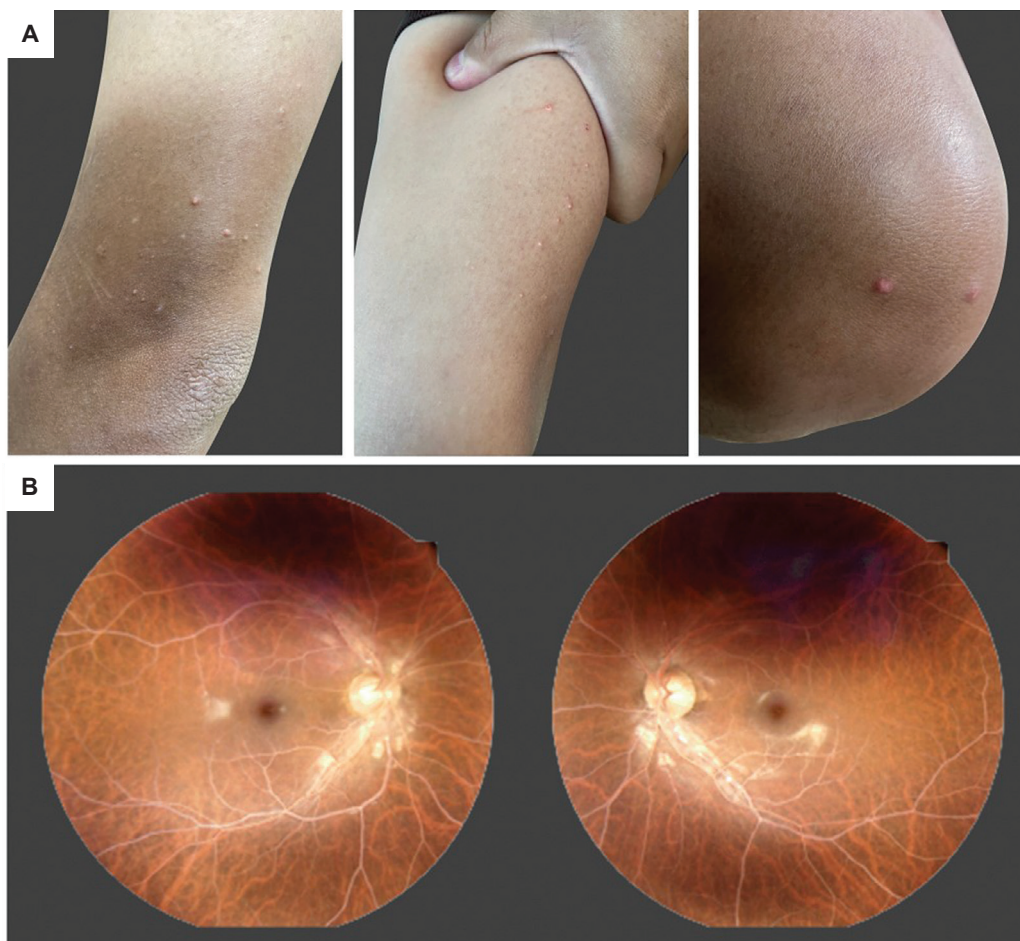
Yotsapon Thewjitcharoen, Natthakan Saiwaew, Soontaree Nakasatien, Thep Himathongkam

*Diabetes and Thyroid Center, Theptarin Hospital, Bangkok, Thailand*

**Key words:** *chylomicronemia, eruptive xanthoma, lipemia retinalis*

Since May 2022, monkeypox outbreaks have been reported in several countries outside Africa. The typical skin lesions of monkeypox begin as papules that appear in possible areas of inoculation, such as the skin or mucous membranes, followed by generalized pustules. Systemic symptoms appear simultaneously or a few days earlier than the lesions.

High levels of chylomicrons in the blood cause the milky appearance of the serum, retinal vessels and eruptive xanthomas.<sup>1</sup> Eruptive xanthomas are characterized by sudden eruptions of multiple erythematous to yellowish, dome-shaped papules on the extensor surfaces of the extremities, buttocks and hands.<sup>2</sup> However, they may present atypically as discrete vesicles or pseudo-pustules<sup>3</sup>



**Figure 1.** (A) A skin eruption that had appeared as erythematous-yellow, dome-shaped papules (2-7 mm in size) over the forearms, elbows, knees, and inner thighs. (B) Digital fundus microscopy revealed a stage III lipemia retinalis (salmon-colored retina with all vessels having milky appearance). The arteries and veins become indistinguishable.

that may easily be confused with other dermatologic manifestations of systemic diseases such as monkeypox. Many of the patients with monkeypox presented with atypical symptoms not seen in previous outbreaks.<sup>4</sup> Additionally, these patients had fewer lesions than usual and did not present with a prodromal period.<sup>5</sup> Our present case highlights the importance of careful history-taking and physical examination in patients with skin lesions. Although the monkeypox rash may be similar to xanthomas in size and shape, they are usually vesicular with lesions in the same stage of development.

A 35-year-old Thai male with a history of obesity, multifactorial chylomicronemia and ketosis-prone type 2 diabetes mellitus presented with sudden-onset multiple skin papules on both arms and legs without fever two days after returning from Kuala Lumpur, Malaysia. He denied any associated symptoms like shortness of breath, abdominal pain or blurred vision. He denied unprotected sexual contact and close contact with an infected person or animal. Skin lesions appeared as multiple erythematous-yellow, dome-shaped papules on the extensor surfaces of the extremities and inner thighs without facial involvement. Based on his medical conditions and the characteristics of the lesions, eruptive xanthomas were suspected rather than pox-like vesicles. Fundus microscopy revealed a stage III lipemia retinalis or a salmon-colored retina with all vessels having a milky appearance. Subsequent investigations showed fasting hypertriglyceridemia at 12,590 mg/dL and hyperglycemia (270 mg/dL) with mild ketonemia (plasma ketone 1.6 mmol/L). Additional history-taking revealed that the patient consumed excessive amounts of fast food and soft drinks during his trip abroad. The patient was advised to consult with a dietitian and to limit fat and simple carbohydrate intake. He was prescribed fenofibrate and omega-3 fatty acids for hypertriglyceridemia and insulin for glycemic control. One week later, skin lesions resolved and lipemia retinalis disappeared once plasma triglyceride was lowered to 546 mg/dL.

#### Ethical Consideration

Patient consent was obtained before submission of the manuscript.

#### Statement of Authorship

All authors certified fulfilment of ICMJE authorship criteria.

#### Author Contribution Statement

YT conceived the idea, verified the results of the study, collected and analyzed the data, prepared the initial draft, reviewed and edited the manuscript, prepared the data presentation. NS provided study materials, curated the data. SN programmed the software, curated the data, managed the research activity planning and execution. TH supervised the research activity planning and execution and acquired financial support for the study.

#### Author Disclosure

The authors declared no conflict of interest.

#### Funding Source

None.

#### References

1. Thomas PK, Smith EB. Ocular manifestations in idiopathic hyperlipidaemia and xanthomatosis. *Br J Ophthalmol* 1958;42(8): 501-6. <https://doi.org/10.1136/bjo.42.8.501>.
2. Goldberg RB, Chait A. A Comprehensive Update on the Chylomicronemia Syndrome. *Front Endocrinol (Lausanne)*. 2020;11: 593931. PMID: 33193106. PMCID: PMC7644836. <https://doi.org/10.3389/fendo.2020.593931>.
3. Roga G, Jithendriya M. Eruptive xanthoma: Warning sign of systemic disease. *Cleve Clin J Med*. 2016;83(10):715-6. PMID: 27726830. <https://doi.org/10.3949/ccjm.83a.15126>
4. Thornhill JP, Barkati S, Walmsley S, et al. Monkeypox virus infection in humans across 16 countries - April-June 2022. *N Engl J Med*. 2022;387(8):679-91. PMID: 35866746. <https://doi.org/10.1056/nejmoa2207323>
5. Català A, Clavo Escribano P, Riera J, et al. Monkeypox outbreak in Spain: Clinical and epidemiological findings in a prospective cross-sectional study of 185 cases. *Br J Dermatol*. 2022. PMID: 35917191. <https://doi.org/10.1111/bjd.21790>

Authors are required to accomplish, sign and submit scanned copies of the JAFES Author Form consisting of: (1) Authorship Certification, that authors contributed substantially to the work, that the manuscript has been read and approved by all authors, and that the requirements for authorship have been met by each author; (2) the Author Declaration, that the article represents original material that is not being considered for publication or has not been published or accepted for publication elsewhere, that the article does not infringe or violate any copyrights or intellectual property rights, and that no references have been made to predatory/suspected predatory journals; (3) the Author Contribution Disclosure, which lists the specific contributions of authors; (4) the Author Publishing Agreement which retains author copyright, grants publishing and distribution rights to JAFES, and allows JAFES to apply and enforce an Attribution-Non-Commercial Creative Commons user license; and (5) the Conversion to Visual Abstracts (\*optional for original articles only) to improve dissemination to practitioners and lay readers. Authors are also required to accomplish, sign, and submit the signed ICMJE form for Disclosure of Potential Conflicts of Interest. For original articles, authors are required to submit a scanned copy of the Ethics Review Approval of their research as well as registration in trial registries as appropriate. For manuscripts reporting data from studies involving animals, authors are required to submit a scanned copy of the Institutional Animal Care and Use Committee approval. For Case Reports or Series, and Images in Endocrinology, consent forms, are required for the publication of information about patients; otherwise, appropriate ethical clearance has been obtained from the institutional review board. Articles and any other material published in the JAFES represent the work of the author(s) and should not be construed to reflect the opinions of the Editors or the Publisher.