

## Thyroid Imaging Reporting and Data System (TIRADS) in Stratifying Risk of Thyroid Malignancy at The Medical City

Joanna Grace Dy,<sup>1</sup> Ruben Kasala,<sup>1</sup> Christy Yao,<sup>1</sup> Rennee Ongoco,<sup>2</sup> Dondee Jules Mojica<sup>2</sup>

<sup>1</sup>Section of Endocrinology, Diabetes and Metabolism, Department of Medicine, The Medical City, Philippines

<sup>2</sup>Department of Radiology, The Medical City, Philippines

### Abstract

**Objective.** To determine the accuracy of Thyroid Imaging Reporting and Data System (TIRADS) in detecting thyroid malignancy, determine risk of malignancy in each TIRADS category and determine the ultrasound characteristics associated with malignancy.

**Methodology.** This is a retrospective cross-sectional study involving patients who underwent ultrasound, thyroid fine needle aspiration biopsy (FNAB) and thyroidectomy at The Medical City from January 2014 to December 2015. Ultrasound reports were retrieved and reviewed by two radiologists on separate occasions who were blinded to the cytopathology and histopathology results. The histopathology reports were correlated with ultrasound features to determine features associated with malignancy. Stata SE 12 was used for data analysis. TIRADS sensitivity, specificity, positive predictive values and negative predictive values and accuracy were calculated.

**Results.** 149 patients with thyroid nodules were included. Solid composition is the ultrasound feature predictive of malignancy with adjusted OR 4.912 (95% CI 1.3257 to 18.2011,  $p=0.017$ ). The risk of malignancy for TIRADS categories 3, 4a, 4b, 4c and 5 were 12.50%, 12.82%, 26.19%, 53.70% and 66.67%, respectively. The Crude OR (95% CI) for TIRADS 4a, 4b, 4c and 5 were 1.03 (0.10 to 10.23), 2.48 (0.27 to 22.54), 8.12 (0.93 to 70.59) and 14.0 (0.94 to 207.60), respectively. The sensitivity, specificity, PPV, NPV and accuracy of TIRADS in relation to surgical histopathology report were 98.00%, 7.07%, 34.75%, 87.50%, and 53% respectively in TIRADS categories 4 and 5.

**Conclusion.** This study showed that a solid nodule is the most frequent ultrasound feature predictive of thyroid malignancy. Higher TIRADS classification is associated with higher risk of thyroid malignancy. TIRADS is a sensitive classification in recognizing patients with thyroid cancer.

**Key words:** thyroid imaging reporting and data system, histopathology, thyroid cancer, malignancy risk

### INTRODUCTION

Thyroid nodules are prevalent in the general population. The prevalence rates of thyroid nodules range from 2-35% depending on the study population.<sup>1,2</sup> In the Philippines, the estimated prevalence of nodular goiter is 8.9%.<sup>3</sup> Thyroid nodules are usually asymptomatic but due to the increased use of ultrasound imaging, detection of incidental thyroid nodules has also increased. Ultrasound allows the identification of a wide spectrum of sizes and characteristics that result in difficulty selecting nodules for fine needle aspiration biopsy (FNAB). Sonographic findings suggestive of malignancy are solid nodules, nodule hypoechoogenicity or marked hypoechoogenicity, irregular margins, microcalcifications and a shape taller than wide on a transverse view.<sup>4</sup> Fine needle aspiration biopsy is a simple procedure and is the preferred initial diagnostic method for the evaluation of thyroid nodules. The sensitivity and specificity for FNAB in published series range between 65% to 98% and 73% to 100%.<sup>5</sup>

Histopathology is the gold standard to evaluate the effectiveness of the fine needle aspiration of thyroid nodules to reliably diagnose thyroid malignancy.<sup>6</sup> Most of the thyroid nodules biopsied are benign and only approximately 3-7% of thyroid FNAB are malignant.<sup>7</sup> With this, it is important to use an ultrasound classification that will help differentiate benign from malignant thyroid nodules to decrease unnecessary biopsy.

Several studies regarding Thyroid Imaging, Reporting and Data System (TIRADS) were done since 2009. This was patterned from the widely used and acceptable breast imaging reporting and data system (BIRADS) which showed a number of significant parameters for the quantitative analysis of ultrasound features.<sup>8-10</sup> In BIRADS, it is important to differentiate category 3 which is probably benign, from category 4 which is suspicious for malignancy, because management for category 3 is just follow-up imaging, while management for category 4 is biopsy.<sup>11</sup> In a study by Horvath et al., patients with

TIRADS 3 should be followed up while patients with TIRADS 4 and 5 nodules must be biopsied or later operated on since malignancy rate for TIRADS 3 was less than 5% while for TIRADS 4 it was at 5-80%.<sup>8</sup>

TIRADS category ranges from TIRADS 1 to TIRADS 5. TIRADS 1 corresponds to normal thyroid gland, TIRADS 2: benign nodules, TIRADS 3: probably benign nodules, TIRADS 4: with ultrasound features suspicious of malignancy, TIRADS 5: nodules highly suggestive of malignancy. Although studies were made regarding TIRADS, they used complex systems which may be difficult to apply in our institution. A study by Horvath et al., was based on 10 ultrasound patterns.<sup>8</sup> Park et al., on the other hand proposed an equation for predicting the probability of thyroid malignancy on the basis of 12 ultrasound features. It is difficult to assign every thyroid nodule into the equation in clinical setting.<sup>9</sup> In a study by Kwak et al., a simpler TIRADS scoring was used based on the BIRADS category such as category 3 (no suspicious US features), 4a (one suspicious feature), 4b (two suspicious features), 4c (three or four suspicious features).<sup>10</sup> This study showed a good correlation of the risk of malignancy using TIRADS scoring.

Filipinos are reported to have a high incidence of thyroid cancer.<sup>12-14</sup> In a local study by Puno-Ramos et al., only microcalcification was associated with thyroid malignancy.<sup>15</sup> In a study by Cañete et al., it showed that firm to hard, microcalcification and irregular margins were significant predictors of thyroid malignancy which was similar to international data.<sup>16</sup> However no data regarding the use of TIRADS in a local setting has been reported. Although foreign studies have been done regarding TIRADS, it is important to validate it against local data to determine its applicability in our setting so as to avoid unnecessary biopsy.

The aim of this study is to determine the accuracy of thyroid imaging reporting and data system in detecting thyroid malignancy in comparison to histopathology report.

## GENERAL OBJECTIVE

To determine the accuracy of Thyroid Imaging Reporting and Data System (TIRADS) in detecting thyroid malignancy in patients with thyroid nodules

## SPECIFIC OBJECTIVES

To determine the ultrasound characteristics of patients with thyroid nodules associated with thyroid malignancy.

To determine the risk of malignancy in each Thyroid Imaging Reporting and Data System (TIRADS) category.

To determine the sensitivity, specificity, PPV and NPV of TIRADS in detecting malignancy of patients with thyroid nodules with surgical histopathology as gold standard.

## METHODOLOGY

### Study Design

This was a retrospective, cross sectional study approved by our institutional review board. The requirement to obtain informed consent was waived.

### Study Subjects

All Filipino adults who underwent thyroid ultrasound, fine needle aspiration biopsy and thyroidectomy at The Medical City from January 2014 to December 2015 were included in the study.

### Study Population

A minimum of 167 subjects are required for this study based on a level of significance of 5%, a prevalence of 76.13%, sensitivity of 99.6% (95% CI: 98.9-100). The values for the prevalence of malignant nodules and sensitivity of the TIRADS 4 were based from the study by Horvath et al., Prospective validation of the ultrasound based TIRADS classification: results in surgically resected thyroid nodules.

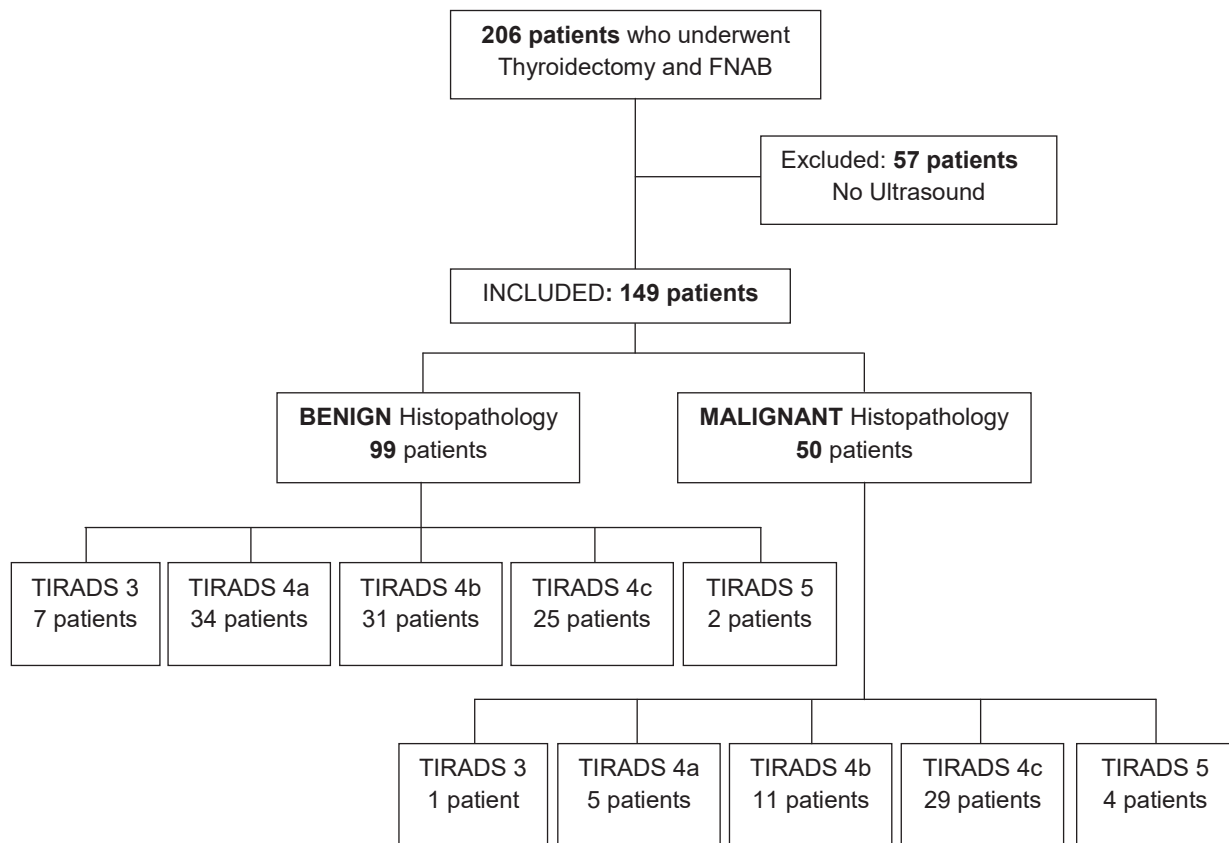
### Description of Study Procedure

Cytopathology and histopathology records of all patients from January 2014 to December 2015 with thyroid nodules on ultrasound for which FNAB and surgical management were done at The Medical City were gathered from the Department of Clinical Pathology. Patient confidentiality was maintained hence no patient identifiers were used; instead subjects were assigned a number. Records without available digital thyroid ultrasound images and those with indeterminate or suspicious for malignancy on cytology that did not undergo surgery were excluded from the study.

Cytopathologic diagnosis was reported using the Bethesda System of classification.<sup>7</sup>

The ultrasound scans of the thyroid gland performed between 2014 and 2015 that were stored in Siemens Syngo Viewer were reviewed. Two radiologists, a resident with four-year training experience and one consultant with more than ten years of experience, reviewed the thyroid ultrasounds. Both were blinded to both the cytopathology and histopathology reports. The two radiologists reviewed the ultrasound imaging on separate occasions. In the event of discrepancies, the reading of the consultant was followed.

All thyroid nodules were characterized according to composition, echogenicity, margins, calcification and shape. Composition was either solid or mixed. A solid nodule was defined as a purely solid or predominantly solid with a cystic component comprising less than 10% of the total volume. Mixed nodule revealed features of both solid and cystic (anechoic on ultrasound).



**Figure 1.** Summary of patient population and TIRADS classification.

Echogenicity was either classified as hyperechogenicity, isoechogenicity, hypoechogenicity or marked hypoechogenicity. Hyperechogenicity was defined as echogenicity of the nodule more than that of the adjacent thyroid parenchyma, while isoechogenicity showed similar echogenicity to the surrounding thyroid parenchyma. Hypoechogenicity was characterized as echogenicity less than that of the adjacent thyroid parenchyma but more than that of the surrounding strap muscle, while marked hypoechogenicity was described as echogenicity that was less than the strap muscle.

The margins were classified as regular, microlobulated or irregular. Regular margin was when the border was smooth, distinct, well defined and with regular outline, while microlobulated margin was defined as the presence of many small lobules on the surface of a nodule and irregular margin was when the border is ill-defined, not smooth and with indistinct interface between the nodule and adjacent thyroid parenchyma.

Calcifications when present, were categorized as either microcalcification or macrocalcification. Microcalcifications were described as tiny, hyperechoic foci less than 1.0 mm in size with no comet-tail artifacts while macrocalcifications were hyperechoic foci larger than 1.0 mm. Shape was categorized as taller than wide when anteroposterior dimension was greater than the transverse dimension, while wider than tall was defined as transverse dimension greater than anteroposterior dimension.

Kwak classification was used in this study and nodules were classified into TIRADS category (1, 2, 3, 4a, 4b, 4c, 5) based on ultrasound features.<sup>10</sup>

**Data Analysis**

Frequency and percentage, mean and standard deviation were used to summarize the clinical characteristics of patients. A two-way table was constructed to determine accuracy measures (sensitivity, specificity, predictive values, likelihood ratios) of TIRADS compared to histopathology. We used simple logistic regression to determine crude associations of surgical histopathologic malignancy with patients’ demographic and clinical characteristics. The ultrasound features associated with malignancy were determined by multiple regression analysis. Crude and adjusted odds ratios and their corresponding 95% confidence intervals were determined. Null hypotheses were rejected at 0.05 alpha level of significance. STATA v12 software was used.

**RESULTS**

We had a total of 206 patients who underwent thyroidectomy and FNAB, of which 57 patients were excluded because these patients had no thyroid ultrasound reports. We analyzed a total of 149 patients, of whom 50 (33.56%) were confirmed to be malignant via histopathology (Figure 1).

Majority of patients were in their 30s (23%), 40s (22%), or 50s (22%). The mean age was  $46.91 \pm 13.57$ . There were more females (87%) than males. The most frequent characteristics of nodules on ultrasound were solid in composition (62%), hypoechoic (38%) or isoechoic to hyperechoic (36%), well-circumscribed (41%), and wider than tall (83%). Microcalcifications were present in 24% of nodules, while macrocalcifications were seen in 19%. Patients with TIRADS 4a, 4b, and 4c comprised 26%, 28%, and 36% of the group, respectively. About 55% of nodules were classified as benign by Bethesda system after FNAB. On the other hand, final histopathologic diagnosis was benign in 66% of resected specimens (Table 1).

**Table 1.** Demographic and clinical profile of thyroidectomy patients (n=149)

Age (years)	
Below 30	17 (11.41)
30-39	34 (22.82)
40-49	33 (22.15)
50-59	33 (22.15)
60-69	29 (19.46)
70 and above	3 (2.01)
Age (years)	$46.91 \pm 13.57$
Sex	
Female	129 (86.58)
Male	20 (13.42)
Composition	
Solid	93 (62.42)
Mixed	56 (37.58)
Echogenicity	
Hyperchoic or isoechoic	53 (35.57)
Hypoechoic	56 (37.58)
Markedly hypoechoic	40 (26.85)
Margins	
Well-circumscribed	61 (40.94)
Microlobulated	36 (24.16)
Irregular	52 (34.90)
Calcifications	
Microcalcifications	36 (24.16)
Macrocalcifications	29 (19.46)
None	84 (56.38)
Shape	
Wider than tall	123 (82.55)
Taller than wide	26 (17.45)
TIRADS category	
3	8 (5.37)
4a	39 (26.17)
4b	42 (28.19)
4c	54 (36.24)
5	6 (4.03)
Bethesda classification	
I	13 (8.72)
II	82 (55.03)
III	12 (8.05)
IV	11 (7.38)
V	27 (18.12)
VI	4 (2.68)
Surgical histopathology	
Benign	99 (66.44)
Malignant	50 (33.56)

Bethesda classification: I, non-diagnostic; II, benign; III, atypia of undetermined significance; IV, follicular neoplasm; V, suspicious for malignancy; VI, malignant.

TIRADS categories: 3, probably benign; 4a, one suspicious malignant feature on ultrasound; 4b, two suspicious malignant features on ultrasound; 4c, three or four suspicious malignant features on ultrasound; 5, five suspicious malignant features on ultrasound.

Values are expressed as frequency (%), mean  $\pm$  SD

We compared select characteristics between patients with malignant versus benign thyroid nodules. Compared to mixed nodules, patients with a solid composition was 7.48 times as likely to have a malignant nodule (OR 7.48 95% CI 2.92 to 19.15,  $p<0.001$ ). Those with markedly hypoechoic nodules were three times more likely to have a malignant nodule (OR 3.42 95% CI 1.40 to 8.25,  $p=0.007$ ). Nodules with irregular margins were four times more likely to be malignant (OR 3.99, 95% CI 1.76 to 9.05,  $p=0.001$ ). Compared to patients without calcifications, patients with macrocalcifications were less likely to be malignant (OR 0.34, 95% CI 0.15 to 0.79,  $p=0.012$ ) (Table 2).

FNAB results according to Bethesda classification were: Bethesda I 8.72%, Bethesda II 55.03%, Bethesda III 8.05%, Bethesda IV 7.38%, Bethesda V 18.12%, Bethesda VI 2.68% (Table 3).

We conducted a stepwise logistic regression to determine predictors of malignant thyroid nodules. We found the following characteristics to predict malignant nodules: solid composition and higher Bethesda classes (Table 4). Our model explains 40% in the variability of the histopathology results ( $p<0.001$ ).

The malignancy risk of TIRADS category 3, 4a, 4b, 4c and 5 were 12.5% (1 out of 8), 12.82% (5 out of 39), 38.10% (11 out of 29), 57.41% (29 out of 54) and 66.67% (4 out of 6), respectively. The crude odds ratio for TIRADS 4a, 4b, 4c and 5 were: 1.03 (0.10 to 10.23), 2.48 (0.27 to 22.54), 8.12 (0.93 to 70.59) and 14.0 (0.94 to 207.60), respectively. We had insufficient evidence to demonstrate a difference in TIRADS grading distribution between malignant and benign nodules (Table 5).

On comparing TIRADS results and histopathology, we found that TIRADS 4a to 5 classes had approximately 98% sensitivity, 7.07% specificity, LR+ of 1.05, LR- of 0.28, PPV of 34.75%, NPV of 87.5%, and accuracy of 53% (Table 6).

## DISCUSSION

Ultrasonography of the thyroid gland even in asymptomatic patients increased the detection of thyroid nodules in the general population.<sup>17</sup> Current guideline for adult patients with thyroid nodules and differentiated thyroid cancer by the American Thyroid Association (ATA) 2015 recommended fine needle aspiration biopsy (FNAB) for the following: (1) thyroid nodules measuring 1 cm and above with intermediate to high sonographic pattern; (2) thyroid nodules with low suspicious pattern measuring 1.5 cm and above; and (3) thyroid nodules with very low suspicious ultrasound pattern measuring 2 cm and above.<sup>4</sup> Ultrasound features are important in predicting risk of malignancy. According to ATA, high suspicion ultrasonographic pattern is characterized as solid hypoechoic nodule or solid hypoechoic component of a partially cystic nodule with one or more of the

**Table 2.** Association of patient characteristics with malignancy at surgical histopathology (n=149)

	Malignant (n=50)	Benign (n=99)	Crude Odds Ratio (95% Confidence Interval)	P-Value
Age (years)				
Below 30	9 (18)	8 (8.08)	(reference)	-
30-39	8 (16)	26 (26.26)	0.27 (0.08 to 0.94)	<b>0.040</b>
40-49	11 (22)	22 (22.22)	0.44 (0.13 to 1.47)	0.184
50-59	11 (22)	22 (22.22)	0.44 (0.13 to 1.47)	0.184
60-69	10 (20)	19 (19.19)	0.47 (0.14 to 1.59)	0.223
70 and above	1 (2)	2 (2.02)	0.44 (0.03 to 5.88)	0.538
Age (years)	46.46 ± 14.93	47.13 ± 12.91	0.996 (0.97 to 1.02)	0.775
Sex				
Female	43 (86)	86 (86.87)	(reference)	-
Male	7 (14)	13 (13.13)	1.08 (0.40 to 2.90)	0.883
Composition				
Mixed	6 (12)	50 (50.51)	(reference)	-
Solid	44 (88)	49 (49.49)	7.48 (2.92 to 19.15)	<b>&lt;0.001</b>
Echogenicity				
Hyperechoic or isoechoic	12 (24)	41 (41.41)	(reference)	-
Hypoechoic				
Markedly hypoechoic	18 (36)	38 (38.38)	1.62 (0.69 to 3.80)	0.269
	20 (40)	20 (20.20)	3.42 (1.40 to 8.35)	<b>0.007</b>
Margins				
Well-circumscribed	13 (26)	48 (48.48)	(reference)	-
Microlobulated	10 (20)	26 (26.26)	1.42 (0.55 to 3.58)	0.471
Irregular	27 (54)	25 (25.25)	3.99 (1.76 to 9.05)	<b>0.001</b>
Calcifications				
None	18 (36)	66 (66.67)	(reference)	-
Microcalcifications	16 (32)	20 (20.20)	1.54 (0.58 to 4.11)	0.391
Macrocalcifications	16 (32)	13 (13.13)	0.34 (0.15 to 0.79)	<b>0.012</b>
Shape				
Wider than tall	37 (74)	86 (86.87)	(reference)	-
Taller than wide	13 (26)	13 (13.13)	2.32 (0.98 to 5.49)	0.055
Bethesda classification				
I or II	13 (26)	82 (82.83)	(reference)	-
III	7 (14)	5 (5.05)	8.83 (2.44 to 32.02)	<b>0.001</b>
IV	2 (4)	9 (9.09)	1.40 (0.27 to 7.23)	0.687
V	24 (48)	3 (3.03)	50.46 (13.28 to 191.80)	<b>&lt;0.001</b>
VI	4 (8)	0	1	-
Dimensions				
CC	2.49 ± 1.20	3.06 ± 1.39	0.71 (0.54 to 0.94)	<b>0.016</b>
W	1.88 ± 0.98	2.34 ± 1.20	0.68 (0.49 to 0.95)	<b>0.023</b>
AP	1.66 ± 0.87	1.86 ± 0.95	0.79 (0.54 to 1.15)	0.215

Bethesda classification: I, non-diagnostic; II, benign; III, atypia of undetermined significance; IV, follicular neoplasm; V, suspicious for malignancy; VI, malignant.

CC = craniocaudal ; W = Width ; AP = Anteroposterior

Values are expressed as frequency (%), mean ± SD or median (range)

following features: irregular margins, microcalcifications, taller than wide shape, rim calcifications with small extrusive soft tissue component and with evidence of extrathyroidal extension.

Intermediate suspicious sonographic pattern is described as thyroid nodules with hypoechoic features with smooth margins without microcalcification, extrathyroidal extension or taller than wide shape.

Low suspicion sonographic pattern is described as isoechoic or hyperechoic solid nodule or partially cystic nodule with eccentric solid areas without microcalcification, irregular margin or extrathyroidal extension or taller than wide shape, while very low suspicion sonographic pattern is characterized as spongiform or partially cystic nodules without any of the sonographic features described in low, intermediate or high suspicion patterns.

**Table 3.** Bethesda classification

Bethesda	Histopathology		
	All (n = 149)	Malignant (n=50)	Benign (n=99)
	Frequency (%)		
<b>Bethesda I</b>	13 (8.72)	0 (0)	13 (100)
<b>Bethesda II</b>	82 (55.03)	13 (15.85)	69 (84.15)
<b>Bethesda III</b>	12 (8.05)	7 (58.33)	5 (41.67)
<b>Bethesda IV</b>	11 (7.38)	2 (18.18)	9 (81.82)
<b>Bethesda V</b>	27 (18.12)	24 (88.99)	3 (11.11)
<b>Bethesda VI</b>	4 (2.68)	4 (100)	0 (0)

Bethesda classification: I, non-diagnostic; II, benign; III, atypia of undetermined significance; IV, follicular neoplasm; V, suspicious for malignancy; VI, malignant

The malignancy risks recommended by the ATA are more than 70-90% for the high suspicion pattern, 10-20% for the intermediate suspicion pattern, 5-10% for the low suspicion pattern, less than 3% for the very low suspicion pattern and less than 1% for the benign pattern.<sup>4</sup>

**Table 4.** Clinical features associated with malignant thyroid nodules at surgical histopathology (n=149)

	Adjusted Odds Ratio	95% Confidence Interval	P-Value
Age (years)			
Below 30	(reference)	-	-
30-39	0.2823	0.0402 to 1.9818	0.203
40-49	0.4061	0.0612 to 2.6961	0.351
50-59	0.4125	0.0606 to 2.8058	0.365
60-69	0.1135	0.0146 to 0.8849	<b>0.038</b>
70 and above	0.1076	0.0009 to 12.5138	0.358
Male	0.6446	0.1113 to 3.7339	0.624
Solid composition	4.9122	1.3257 to 18.2011	<b>0.017</b>
Echogenicity			
Hyperechoic or isoechoic	(reference)	-	-
Hypoechoic	1.9757	0.6069 to 6.4319	0.258
Markedly hypoechoic	3.6708	0.8463 to 15.9214	0.082
Margins			
Well-circumscribed	(reference)	-	-
Microlobulated	2.0423	0.5823 to 7.1637	0.265
Irregular	1.6792	0.4940 to 5.7073	0.406
Bethesda classification			
I or II	(reference)	-	-
III	7.4988	1.5572 to 36.1108	<b>0.012</b>
IV	1.9548	0.3329 to 11.4788	0.458
V	36.7881	8.1908 to 165.2305	<b>&lt;0.0001</b>
VI	-	-	-

P-value < 0.0001; R<sup>2</sup> = 40.82%

**Table 5.** TIRADS categories and risk of malignancy of patients who underwent thyroidectomy (n=149)

TIRADS	Histopathology		Risk of Malignancy (%)	Crude Odds Ratio (95% Confidence Interval)	P - Value
	Malignant (n=50)	Benign (n=99)			
<b>TIRADS 3</b>	1/8	7/8	12.50%	(reference)	-
<b>TIRADS 4a</b>	5/39	34/39	12.82%	1.03 (0.10 to 10.23)	0.980
<b>TIRADS 4b</b>	11/42	31/42	38.10%	2.48 (0.27 to 22.54)	0.419
<b>TIRADS 4c</b>	29/54	25/54	57.41%	8.12 (0.93 to 70.59)	0.059
<b>TIRADS 5</b>	4/6	2/6	66.67%	14.0 (0.94 to 207.60)	0.055

TIRADS categories: 3, probably benign; 4a, one suspicious malignant feature on ultrasound; 4b, two suspicious malignant features on ultrasound; 4c, three or four suspicious malignant features on ultrasound; 5, five suspicious malignant features on ultrasound

**Table 6.** Accuracy of TIRADS in predicting a malignant thyroid nodule (n=149)

TIRADS	Histopathology		Total
	Malignant (n=50)	Benign (n=99)	
<b>TIRADS 4a to 5</b>	49 (98)	92 (92.93)	141 (94.63)
<b>TIRADS 3</b>	1 (2)	7 (7.07)	8 (5.37)
<b>Total</b>	50 (100)	99 (100)	149 (100)
Sensitivity	98 (89.35 to 99.95)	Positive LR	1.05 (0.99 to 1.13)
Specificity	7.07 (2.89 to 14.03)	Negative LR	0.28 (0.04 to 2.24)
PPV	34.75 (33.24 to 36.29)		
NPV	87.5 (46.96 to 98.23)	Accuracy	53%

PPV, positive predictive value; NPV, negative predicted value; LR, likelihood ratio  
Values are expressed as frequency (%) or median (range)

In our study, solid composition was 7.48 times likely to have a malignant nodule (OR 7.48 95% CI 2.92 to 19.15,  $p < 0.001$ ). While those nodules with marked hypoechoic nodules were three times more likely to have a malignant nodule (OR 3.42 95% CI 1.40 to 8.25,  $p = 0.007$ ). Nodules with irregular margins on the other hand were four times more likely to be malignant (OR 3.99, 95% CI 1.76 to 9.05,  $p = 0.001$ ). But on adjusted OR, solid nodule was the only ultrasound feature predictive of malignancy with OR 4.912 (95% CI 1.3257 to 18.2011,  $p = 0.017$ ). While a local study published by Puno-Ramos et al., it showed that only the presence of microcalcification on ultrasound had a significant correlation with malignancy with odds ratio of 11.3 and it also showed that a nodule

with more than two ultrasound features predictive of malignancy was more likely to be malignant on cytopathology with p-value of 0.00.<sup>15</sup> Smith-Bindman et al., also studied ultrasound imaging characteristics associated with malignant nodules and showed that three ultrasound nodule characteristics which were microcalcification (odd ratio (OR), 8.1; 95% CI, 3.8-17.3), size greater than 2 cm (OR 3.6; 95% CI, 1.7-7.6) and an entirely solid composition (OR, 4.0; 95% CI, 1.7-9.2) were statistically significant in predicting thyroid malignancy.<sup>18</sup> In a meta-analysis done by Remonti et al., on the other hand revealed that solid nodule, hypoechoic nodules, irregular margins, absence of halo, microcalcifications, central vascularization, solitary

nodule, heterogeneity, taller than wide shape and elasticity were all significantly associated with malignancy with odds ratio (OR) ranging from 1.77 to 35.7. But the sensitivity of ultrasound features predictive of malignancy only ranged from 26.7 to 63% and the author concluded that ultrasound features in isolation do not provide reliable guide as when to do FNAB.<sup>19</sup>

Fine needle aspiration biopsy is the preferred initial diagnostic method for the evaluation of thyroid nodules. Most of the thyroid nodules biopsied are benign and only approximately 3-7% of thyroid FNAB are malignant.<sup>7</sup> The sensitivity and specificity for FNAB in published series range between 65% to 98% and 73 to 100%, respectively.<sup>5</sup> In our study the sensitivity of fine needle aspiration biopsy was 60.00% which was slightly lower than the published series but the specificity was comparable at 87.88% with the published studies. Bethesda Classification I is not an uncommon finding. According to Cibas et al., the risk of malignancy for Bethesda I is at 1-4%.<sup>7</sup> But in the study by Bongiovanni et al., the malignancy rate of nondiagnostic FNAB who underwent surgical excision is approximately 17%.<sup>20</sup> In our study, 8.72% of the patients were classified under Bethesda I, of which all their histopathology reports were not malignant. Our patients classified under Bethesda III on the other hand were eight times likely to have malignant nodules (OR 8.0906 95% CI 1.6951 to 38.6160,  $p=0.009$ ) With this, it is important to use an ultrasound classification that will help differentiate benign from malignant thyroid nodules in order to decrease unnecessary biopsy.

Horvath et al., in 2009 first published a study with regards to the use of TIRADS classification. Its main objective was to improve the ultrasound characterization of nodules and establish risk groups for patients who will undergo FNAB.<sup>8</sup> They described 10 ultrasound patterns of thyroid nodules with related risk of malignancy.<sup>8</sup> This was followed by a study by Park et al., which proposed an equation for predicting the probability of malignancy on the basis of 12 ultrasound features.<sup>9</sup> Both studies correlated well with risk of malignancy, however these ultrasound patterns and equations were cumbersome and complex and are not applicable to all thyroid nodules nor in clinical practice. Hence Kwak et al., investigated a practical TIRADS classification for the management of thyroid nodules. Sonographic characteristics predictive of malignancy such as: solid echogenicity, hypoechogenicity or marked hypoechogenicity, microcalcifications, microlobulated or irregular border and taller than wide shape were used to classify TIRADS from 1 to 5. They categorized the TIRADS to 1: normal thyroid gland, 2: benign nodules, 3: probably benign nodules, 4a: one ultrasound feature suggestive of malignancy, 4b: two ultrasound features suggestive of malignancy, 4c: three or four features suggestive of malignancy and 5: five ultrasound features suggestive of malignancy.<sup>10</sup> The study

of Kwak et al., revealed that TIRADS 3 or nodules with no ultrasound features suggestive of malignancy had a fitted probability of malignancy of 0.02-0.028 indicating that biopsy may not be necessary while for nodules with TIRADS 4-5, it had a fitted probability of malignancy of 0.036 for which FNAB is indicated and the results were comparable with the widely accepted BIRADS.<sup>10</sup> In a prospective study by Srinivas et al., they used the TIRADS classification as suggested by Kwak et al., and showed that the classification is a reliable modality in differentiating benign nodules from malignant nodules.<sup>21</sup>

Our study adapted the TIRADS classification used by Kwak et al. It showed that the malignancy risk of TIRADS category 3, 4a, 4b, 4c and 5 were 12.5% (1 out of 8), 12.82% (5 out of 39), 26.19% (11 out of 42), 53.70% (29 out of 54) and 66.67% (4 out of 6), respectively. Since majority of the population had at least one ultrasound feature suggestive of malignancy and only 8 patients had TIRADS 3, the malignancy risk of TIRADS 3 was higher compared to other studies.<sup>8-10,21-24</sup> The histopathology report of the patient who had a malignant result showed follicular carcinoma on top of a micropapillary carcinoma. One patient who also had TIRADS 3 had an incidental finding of micropapillary carcinoma measuring 0.5 cm within the left lobe but the FNAB was done on another nodule that measured 1.87 cm x 1.53 cm x 1.06 cm (CC x W x AP) in the right lobe. The crude odds ratio for TIRADS 4a, 4b, 4c and 5 were: 1.03 (0.10 to 10.23), 2.48 (0.27 to 22.54), 8.12 (0.93 to 70.59) and 14.0 (0.94 to 207.60), respectively. We had insufficient evidence to demonstrate a difference in TIRADS grading distribution between malignant and benign nodules.

The accuracy of TIRADS in our study was 53% which was slightly lower as compared to the studies of Ha et al., at 69.5%<sup>22</sup> and Russ et al., at 62%.<sup>25</sup> The reason for low accuracy is possibly because of a high false positive rate. The overall sensitivity of TIRADS categories 4 and 5 for malignancy was 98.00% which was higher than that reported by Ha et al., (95.5%)<sup>22</sup> and Yoon et al., (97.4%).<sup>24</sup> Although the PPV of this study was 34.75% which was lower as compared to PPVs of Horvath et al.,<sup>8</sup> and Ha et al.,<sup>22</sup> (49% and 44.5% respectively). The specificity of this study was only 7.07% which was also lower compared to other studies (29%-75%).<sup>8,22-24</sup>

In our study, the prevalence of malignancy was higher at 33.56% compared to an FNAB based series wherein malignancy rate was only 3 to 7%.<sup>7</sup> With this, PPV/NPV might be affected since an increase in prevalence leads to increase in PPV. The implication is that a screening test is more efficient in a high risk target population. If the prevalence of the disease is low, the positive predictive value will not be high even if both the sensitivity and specificity are high. When screening the general population, many people with positive test results will be false positives.<sup>26</sup>

Despite the relatively low accuracy, this study showed that TIRADS is a useful screening tool to defer the need for fine needle aspiration biopsy for patients with TIRADS 3 classification. The number of ultrasound features predictive of malignancy is an important guide in determining further management as to whether to observe the nodules or do appropriate intervention such as fine needle aspiration biopsy.

## CONCLUSION

This study showed that presence of solid nodule in the thyroid is predictive of thyroid malignancy. Higher TIRADS classification is associated with higher risk of thyroid malignancy. TIRADS is a sensitive classification in recognizing patients with thyroid cancer and can be used as a guide in deciding the need for fine needle aspiration biopsy.

Ultrasound features such as markedly hypoechoic nodules and nodules with irregular borders were associated with increased likelihood of malignancy but did not reach statistical significance in multivariate analysis.

## Limitations of the Study and Recommendations

The investigators identified a number of limitations to this study. First, the results showed a wide confidence interval which was reflective of a relatively small sample size. Second, this was a retrospective study hence there might be selection bias. All our subjects underwent surgery due to the presence of ultrasound features suggestive of malignancy. Hence, it is worth mentioning that our malignancy rate is higher at 33.56% as compared to an FNAB based series wherein malignancy rate is only 3 to 7%.<sup>7</sup> Third, the study did not represent equally the different TIRADS categories since majority of the population had at least 1 suspicious ultrasound feature suggestive of malignancy. Fourth, it is from a single institution which might not be reflective of the entire population. In order to validate our findings, we recommend a prospective multicenter study in evaluating the use of TIRADS. Once validated, TIRADS may be used as a reference for reporting thyroid pathology and implemented as a standardized coding for all clinicians and radiologists.

## Acknowledgments

The authors thank Pier Angeli D. Medina, MD and Elizabeth Ann S. Alcazaren, MD for providing the cytopathology and histopathology records of patients in this study.

## Statement of Authorship

All authors certified fulfillment of ICMJE authorship criteria.

## Author Disclosure

The authors declared no conflict of interest.

## Funding Source

None.

## References

- Ezzat S, Sarti DA, Cain DR, Braunstein GD. Thyroid incidentalomas. Prevalence by palpation and ultrasonography. *Arch Intern Med.* 1994; 154(16):1838-40. PMID: 8053752.
- Dean DS, Gharib H. Epidemiology of thyroid nodules. *Best Pract Res Clinical Endocrinol Metab.* 2008; 22(6):901-11. PMID: 19041821. <https://doi.org/10.1016/j.beem.2008.09.019>.
- Carlos-Raboca J, Jimeno C, Kho S, et al. The Philippine Thyroid Disease Study (PhilTiDes 1): Prevalence of thyroid disorders among adults in the Philippines. *J ASEAN Fed Endocr Soc.* 2012;27(2):27-33. <https://doi.org/10.15605/jafes.027.01.04>.
- Haugen BR, Alexander EK, Bible KC, et al. 2015 American Thyroid Association management guidelines for adult patients with thyroid nodules and differentiated thyroid cancer: The American Thyroid Association Guidelines Task Force on thyroid nodules and differentiated thyroid cancer. *Thyroid.* 2016;26(1):1-133. PMID: 26462967. PMID: PMC4739132. <https://doi.org/10.1089/thy.2015.0020>.
- Muratli A, Erdogan N, Sevim S, Unal I, Akyuz S. Diagnostic efficacy and importance of fine-needle aspiration cytology of thyroid nodules. *J Cytol.* 2014;31(2):73-8. PMID: 25210233. PMID: PMC4159900. <https://doi.org/10.4103/0970-9371.138666>.
- Chowdhury J, Das S, Maji D. A study on thyroid nodules: Diagnostic correlation between fine needle aspiration cytology and histopathology. *J Indian Med Assoc.* 2008;106(6):389-90. PMID: 18839651.
- Cibas ES, Ali SZ. NCI Thyroid FNA State of the Science Conference. The Bethesda system for reporting thyroid cytopathology. *Am J Clin Pathol.* 2009;132(5):658-65. PMID: 19846805. <https://doi.org/10.1309/AJCPHLMWMI3JV4LA>.
- Horvath E, Majlis S, Rossi R, Franco C, Niedmann JP, Castro A, et al. An ultrasound reporting system for thyroid nodules stratifying cancer risk for clinical management. *J Clin Endocrinol Metab.* 2009;94(5):1748-51. PMID: 19276237. <https://doi.org/10.1210/jc.2008-1724>.
- Park JY, Lee HJ, Jang HW, et al. A proposal for a thyroid imaging reporting and data system for ultrasound features of thyroid carcinoma. *Thyroid.* 2009;19(11):1257-67. PMID: 19754280. <https://doi.org/10.1089/thy.2008.0021>.
- Kwak JY, Kim HH, Yoon JH, Moon HJ, Son EJ, et al. Thyroid imaging reporting and data system for US features of nodules: A step in establishing better stratification of cancer risk. *Radiology.* 2011;260(3):892-9. <https://doi.org/10.1148/radiol.11110206>.
- American College of Radiology. Breast imaging reporting and data system, breast imaging atlas . 4<sup>th</sup> ed. Roston Va: American College of Radiology, 2003.
- Goodman MT, Yoshizawa CN, Kolonel LN. Descriptive epidemiology of thyroid cancer in Hawaii. *Cancer.* 1988;61(6):1272-81. PMID: 3342383.
- Haselkorn T, Bernstein L, Preston-Martin S, Cozen W, Mack WJ. Descriptive epidemiology of thyroid cancer in Los Angeles County, 1972-1995. *Cancer Causes Control.* 2000;11(2):163-70. PMID: 10710201. <https://doi.org/10.1023/A:1008932123830>.
- Gomez SL, Noone AM, Lichtensztajn DY, Scoppa S, Gibson JT, Liu L, et al. Cancer incidence trends among Asian American populations in the United States, 1990-2008. *J Natl Cancer Inst.* 2013;105(15):1096-110. PMID: 23878350. PMID: PMC3735462. <https://doi.org/10.1093/jnci/djt157>.
- Puno-Ramos MPG, Villa ML, Kasala RG, Arzadon J, Alcazaren EAS. Ultrasound features of thyroid nodules predictive of thyroid malignancy as determined by fine needle aspiration biopsy. *Philipp J Intern Med.* 2015;53(2):1-8.
- Cañete EJ, Sison-Peña CM, Jimeno CA. Clinicopathological, biochemical, and sonographic features of thyroid nodule predictive of malignancy among adult Filipino patients in a tertiary hospital in the Philippines. *Endocrinol Metab (Seoul).* 2014;29(4):489-97. PMID: PMC4285043. <https://doi.org/10.3803/EnM.2014.29.4.489>.
- Guth S, Theune U, Aberle J, Galach A, Bamberger CM. Very high prevalence of thyroid nodules detected by high frequency ultrasound examination. *Eur J Clin Invest.* 2009;39(8):699-706. PMID: 19601965. <https://doi.org/10.1111/j.1365-2362.2009.02162.x>.



18. Smith-Bindman R, Lebda P, Feldstein V, Sellami, D, Goldstein RB, Brasic N, et al. Risk of thyroid cancer based on thyroid ultrasound imaging characteristics: Results of a population-based study. *JAMA Intern Med.* 2013;173(19):1788-96. PMID: 23978950. PMCID: PMC3936789. <https://doi.org/10.1001/jamainternmed.2013.9245>.
19. Remonti LR, Kramer CK, Leitao CB, Pinto LCF, Gross JL. Thyroid ultrasound features and risk of carcinoma: A systematic review and meta-analysis of observation studies. *Thyroid.* 2015;25(5):538-50. PMID: 25747526 PMCID: PMC4447137. <https://doi.org/10.1089/thy.2014.0353>.
20. Bongiovanni M, Spitale A, Faquin WC, Mazzucchelli L, Baloch ZW. The Bethesda system for reporting thyroid cytopathology: A meta-analysis. *Acta Cytol.* 2012;56(4):333-9. PMID: 22846422. <https://doi.org/10.1159/000339959>.
21. Srinivas MNS, Amogh VN, Gautam MS, Prathyusha IS, Vikram NR, Retnam MK, et al. A prospective study to evaluate the reliability of thyroid imaging reporting and data system in differentiation between benign and malignant thyroid lesions. *J Clin Imaging Sci.* 2016;6:5. PMID: 27014501. PMCID: PMC4785791. <https://doi.org/10.4103/2156-7514.177551>.
22. Ha EJ, Moon WJ, Na DG, Lee YH, Choi N, Kim SJ, et al. A multicenter prospective validation study for the Korean thyroid imaging reporting and data system in patients with thyroid nodules. *Korean J Radiol.* 2016;17(5):811-21. PMCID: PMC5007410. <https://doi.org/10.3348/kjr.2016.17.5.811>.
23. Horvath E, Silva CF, Majlis S, Rodriguez I, Skoknic V, Castro A, et al. Prospective validation of the ultrasound based TIRADS (Thyroid imaging and reporting data system) classification: Results in surgically resected thyroid nodules. *Eur Radiol.* 2017;27(6):2619-28. PMID: 27718080. <https://doi.org/10.1007/s00330-016-4605-y>.
24. Yoon JH, Lee HS, Kim EK, Moon HJ, Kwak JY. Malignancy risk stratification of thyroid nodules: Comparison between the thyroid imaging reporting and data system and the 2014 American Thyroid Association management guidelines. *Radiology.* 2016;278(3):917-24. PMID: 26348102. <https://doi.org/10.1148/radiol.2015150056>.
25. Russ G, Royer B, Bigorgne C, Rouxel A, Bienvenu-Perrard M, Leehardt L. Prospective evaluation of thyroid imaging and data system on 4550 nodules with or without elastography. *Eur J Endocrinol.* 2013;168(5):649-55. PMID: 23416955. <https://doi.org/10.1530/EJE-12-0936>.
26. Altman DG, Bland JM. Diagnostic tests 2: Predictive values. *BMJ.* 1994; 309(6947):102. PMID: 8038641. PMCID: PMC2540558.

Authors are required to accomplish, sign and submit scanned copies of the JAFES Author Form consisting of: (1) Authorship Certification, that all the requirements for authorship have been met by each author, and that the final version of the manuscript has been read and approved by all authors; (2) the Author Declaration, that the article represents original material that is not being considered for publication or has not been published or accepted for publication elsewhere; (3) the Statement of Copyright Transfer [accepted manuscripts become the permanent property of the JAFES and are licensed with an Attribution-Share Alike-Non-Commercial Creative Commons License. Articles may be shared and adapted for non-commercial purposes as long as they are properly cited]; and the ICMJE form for Disclosure of Potential Conflicts of Interest. For original articles, authors are required to submit a scanned copy of the Ethics Review Approval of their research as well as registration in trial registries as appropriate. For manuscripts reporting data from studies involving animals, authors are required to submit a scanned copy of the Institutional Animal Care and Use Committee approval. For Case Reports or Series, and Images in Endocrinology, consent forms, are required for the publication of information about patients; otherwise, authors declared that all means have been exhausted for securing such consent. Articles and any other material published in the JAFES represent the work of the author(s) and should not be construed to reflect the opinions of the Editors or the Publisher.



Send your paper to the publication pathway.  
 Instructions to Authors at  
[www.ASEAN-endocrinejournal.org](http://www.ASEAN-endocrinejournal.org).