

The Lingering Battle of Persistent Hypoaldosteronism Following Adrenalectomy for Primary Aldosteronism: A Case Report

Jie En Tan, Nor Shaffinaz Yusoff Azmi Merican, Shartiyah Ismail, Noor Rafhati Adyani Abdullah

Endocrine Unit, Department of Medicine, Sultanah Bahiyah Hospital, Ministry of Health, Malaysia

Abstract

Persistent hypoaldosteronism post-adrenalectomy for unilateral primary aldosteronism is not uncommon and should be anticipated in patients with risk factors for development of such condition. Most cases of hypoaldosteronism post-adrenalectomy are transient. However, persistent hypoaldosteronism may occur as a result of delayed recovery of contralateral zona glomerulosa suppression, requiring mineralocorticoid replacement for the prevention or treatment of life-threatening hyperkalemia.

Key words: hypoaldosteronism, post-adrenalectomy, unilateral primary aldosteronism, hyperkalemia

INTRODUCTION

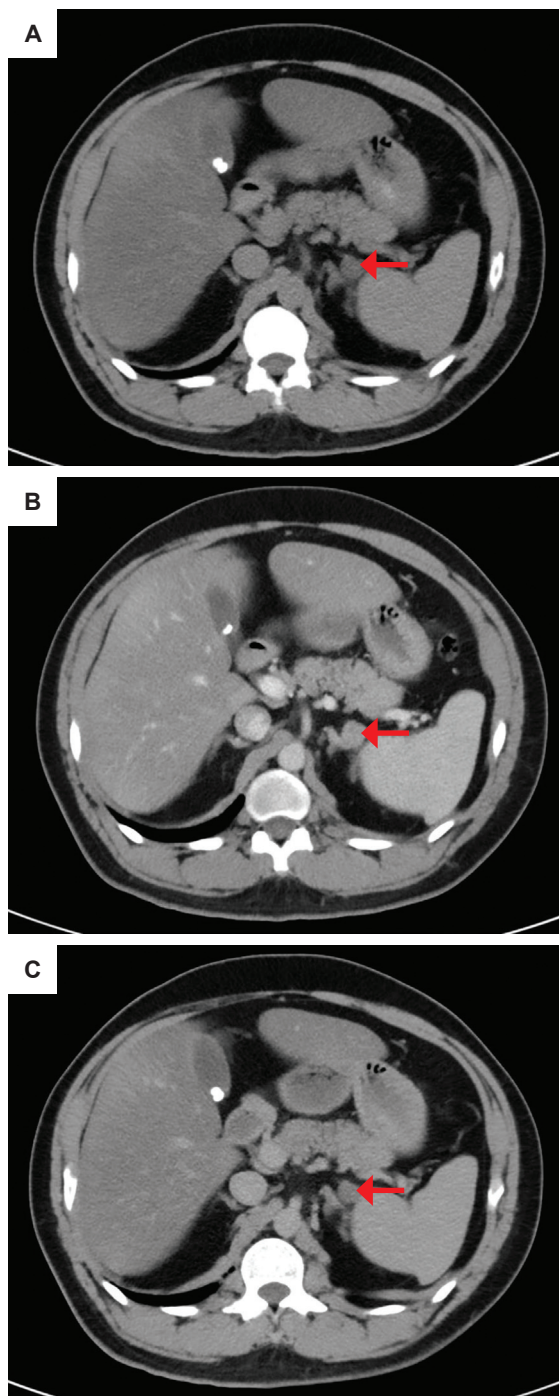
Incidence of persistent hypoaldosteronism post-adrenalectomy for unilateral primary aldosteronism is reported to be between 5%-7.3% of adrenalectomized patients.¹⁻³ Management is challenging due to the lack of clear guidelines or expert consensus to recommend the best practice or follow-up for such cases.

We report a case of persistent hypoaldosteronism that was diagnosed nearly 5 years post-adrenalectomy with the first onset of hyperkalemia occurring at 10 months post-operatively. Hypoaldosteronism was not readily recognized due to the concomitant use of potassium supplement and renin-angiotensin-system (RAS) inhibitors post-operatively and the competing differential diagnosis of type 4 renal tubular acidosis (RTA) secondary to diabetic nephropathy.

CASE

A 58-year-old Malay male was diagnosed with primary aldosteronism in 2016. His primary symptom was an 11-year history of hypertension. At initial presentation, he required three antihypertensive agents, excluding diuretics, with spontaneous hypokalemia requiring potassium supplementation. His plasma aldosterone was 859.4 pmol/L (normal upright: 102.5-1196.6) and direct renin 3.7 mU/L (normal upright: 5.3-99.1), giving an aldosterone renin ratio of 232 pmol/L:mU/L (positive >35) while on non-interfering medications. Plasma aldosterone was not suppressible on a seated saline infusion test, 340.1 pmol/L (normal <170

pmol/L). CT adrenal showed a well-defined homogenous mass abutting the body and lateral limb of the left adrenal gland (Figures 1 and 2), measuring 1.6 cm x 1.7 cm x 1.2 cm. The average attenuation of the adrenal lesion on non-enhanced CT was 8 HU, 70 HU on venous phase and 34 HU on delayed phase, giving an absolute washout of 58.1% and relative washout of 51.4%. Overall, features were suggestive of a left adrenal lipid-rich adenoma. The right adrenal gland was normal in appearance. He underwent continuous cosyntropin infusion with sequential bilateral adrenal venous sampling (AVS) which demonstrated left-sided lateralization; left adrenal vein aldosterone cortisol ratio to right adrenal vein aldosterone cortisol ratio of 9:1 (cortisol-corrected aldosterone ratio from high-side to low-side of more than 4:1 indicates unilateral aldosterone excess).⁴ Both adrenal veins were successfully cannulated with the left and right adrenal vein to peripheral vein cortisol ratio respectively being more than 5:1 (adrenal/peripheral vein cortisol ratio more than 5:1 confirms successful catheterization).⁴ The contralateral suppression index was 0.33, indicating that the aldosterone-cortisol ratio in the contralateral adrenal vein was no higher than the peripheral, again confirming contralateral suppression.⁴ Due to his initial reluctance for operation, he was started on spironolactone. However, at a dose of 50 mg daily he developed gynecomastia and spironolactone was stopped after less than a year of use. His other comorbidities included severe obstructive sleep apnea and Type 2 Diabetes Mellitus (T2DM). He was also overweight with a BMI of 27 kg/m². Of note, his renal profile was normal, creatinine 89 µmol/L and there was presence of microalbuminuria.



Absolute Washout	$\frac{(70 - 34)}{(70 - 8)} \times 100 = \frac{36}{62} \times 100 \approx 58.06\%$
Relative Washout	$\frac{(70 - 34)}{70} \times 100 = \frac{36}{70} \times 100 \approx 51.43\%$

Figure 1. A well-defined homogenous mass (red arrow) seen abutting the body and lateral limb of the left adrenal gland, measuring 1.6 cm x 1.7 cm x 1.2 cm. The average attenuation was 8 HU on non-enhanced CT (A), 70 HU on venous phase (B) and 34 HU on delayed phase (C), with washout characteristics suggestive of left adrenal lipid-rich adenoma.

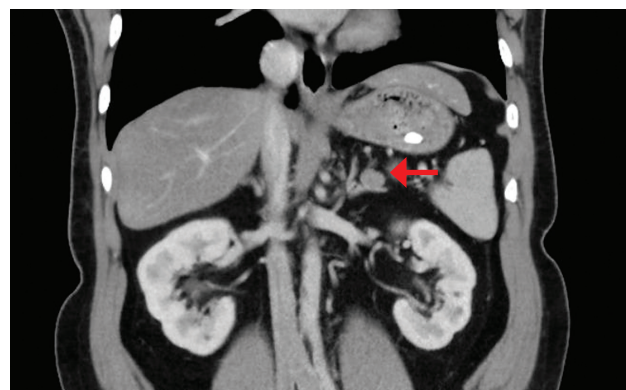


Figure 2. Left adrenal nodule (red arrow) as seen on CT adrenal in coronal view.

Three years after the diagnosis of PA, he underwent laparoscopic left adrenalectomy with histology confirming a benign adrenocortical adenoma and the adrenal nodule size was 2.0 cm x 2.0 cm x 1.5 cm on pathology. Post-operatively, he was kept on a reduced dose of potassium supplement and maintained on perindopril 4 mg daily, bisoprolol 2.5 mg daily and amlodipine 10 mg daily. Potassium level at day 2 post-operation was 3.9 mmol/L (Table 1). Two months later, he was seen in the clinic with a blood pressure of 126/80 mmHg and laboratory results showing potassium level 5.0 mmol/L (3.5-5.1), sodium 136 mmol/L (136-145) and creatinine 98 µmol/L (64-104). He was taken off bisoprolol and potassium supplement while perindopril and amlodipine were both continued.

Ten months after adrenalectomy, he was hospitalized and required emergency treatment for severe hyperkalemia (potassium level 6.3 mmol/L) which entailed a lytic cocktail (consisting of intravenous calcium gluconate, dextrose infusion and intravenous insulin). During his subsequent clinic visits, his potassium level ranged from 4.8 mmol/L to 5.7 mmol/L, coinciding with an increment in his serum creatinine, between 124 µmol/L to 143 µmol/L. He was advised dietary potassium restriction and perindopril was withheld 2 years later. In spite of this, hyperkalemia continued to recur at subsequent clinic visits, culminating in another admission in which lytic cocktail again was given for a potassium of 6.4 mmol/L, followed by a short course of oral calcium polystyrene sulfonate upon discharge.

Type 4 RTA was considered as a cause of the hyperkalemia in view of his background T2DM with microalbuminuria pre-operatively but a normal direct renin level (20.70 mU/L) and resolution of microalbuminuria after adrenalectomy made this diagnosis unlikely.

At 57 months post-adrenalectomy, he remained hyperkalemic (potassium 5.5 mmol/L), with sodium 139 mmol/L and creatinine 140 µmol/L. He was normotensive (blood pressure 135/88 mmHg) on single agent of felodipine 10 mg daily. Fludrocortisone 0.05 mg daily was prescribed empirically for the probable diagnosis of persistent hypoaldosteronism after blood was taken for plasma renin

Table 1. Laboratory results after adrenalectomy and prior to fludrocortisone replacement

Test	Reference range	Post-op Day 2	Jan-2020	Jun-2020	Oct-2020	Jan-2021	Sep-2021	Jan-2022	Sep-2022	Jan-2023	May-2023	Oct-2023	Jan-2024	Aug-2024
Sodium, mmol/L	136 - 145	143	136	NA	133	137	137	137	138	140	138	138	135	139
Potassium, mmol/L	3.5 - 5.1	3.9	5	4.6	6.3	5.1	4.8	5.5	5.4	5.8	6.5	5.6	4.9	5.5
Urea, mmol/L	3 - 9.2	5.1	7.2	NA	8.6	6.5	6.9	7.5	7.1	9.7	11.7	6.4	5.6	7.1
Creatinine, μ mol/L	64 - 104	93	98	124	143	125	118	128	131	171	184	151	126	140

N/A – Not available

and aldosterone levels. Upon review in the clinic two months after initiated on fludrocortisone, potassium level had normalized to 4.7 mmol/L, sodium 142 mmol/L and creatinine stabilized at 125 μ mol/L. Blood investigations prior to mineralocorticoid replacement revealed direct renin concentration to be normal at 39 mU/L (normal upright: 5.3-99.1) whereas plasma aldosterone was undetectable at less than 103 pmol/L.

Five months after fludrocortisone, blood pressure was 138/83 mmHg with potassium 5.1 mmol/L, sodium 136 mmol/L and creatinine at 129 μ mol/L. He did not require further admission following the commencement of fludrocortisone. However, due to the presence of pedal edema, dosage of fludrocortisone was not escalated and oral furosemide was added. Follow-up visit 1 year after the initiation of fludrocortisone, his edema improved on the loop diuretic and he remained normokalemic with latest creatinine level at 109 μ mol/L.

DISCUSSION

Surgery is the definitive treatment for unilateral primary aldosteronism, offering biochemical and/or clinical successes in the majority of cases. In unilateral primary aldosteronism, excess autonomous aldosterone production from the hypersecreting aldosterone-producing adenoma (APA) suppresses renal renin release, resulting in the suppression of the contralateral zona glomerulosa function.³ With adrenalectomy, aldosterone level falls acutely creating a state of hypoaldosteronism as the contralateral zona glomerulosa may take one to four months for functional recovery.³ Patients are at risk for hyperkalemia secondary to hypoaldosteronism made worse by the reduced glomerular filtration rate (GFR) brought about by the reversal of aldosterone-mediated hyperfiltration after surgical intervention.³ The usual recovery of the renin-angiotensin-aldosterone system (RAAS) after unilateral adrenalectomy is relatively rapid, therefore avoiding the need for mineralocorticoid replacement. Reasons for such reversibility are attributed to the presence of other key regulators of aldosterone secretion namely potassium and ACTH which control the contralateral aldosterone production and thus preserve some degree of functional activities in the contralateral adrenal gland.^{1,5} Interestingly, a prospective study by Livia et al., following up on cases of post APA adrenalectomy found that aldosterone took longer than renin to recover (60 vs. 15 days; $p < 0.02$) and patients with higher aldosterone of ≥ 1442.6 pmol/L at diagnosis, had later recovery ($p = 0.03$), indicating that

renin and aldosterone recoveries did not occur at the same rates.⁶ The same study also demonstrated that despite the hypoaldosteronism, ACTH and cortisol levels were unaffected post adrenalectomy.⁶

The term “zona glomerulosa insufficiency” was coined by Fischer et al., and is defined as a state of hypoaldosteronism with undetectable plasma aldosterone level (< 35 ng/L or 67.1 pmol/L) in the presence of hyperkalemia, potassium more than 5.0 mmol/L after adrenalectomy.¹ Hyperkalemia occurring postoperatively can be transient or persistent with the latter being defined as hyperkalemia lasting more than three months and has to be treated medically.¹

Onset of hyperkalemia is described to occur as early as one week to as late as three months post adrenalectomy. In this case, hyperkalemia was detected at 10 months post adrenalectomy while he was still on angiotensin-converting enzyme inhibitor (ACEI), necessitating hospitalization for emergency treatment and correction of hyperkalemia. The occurrence of hyperkalemia was also associated with a sharp rise in creatinine, making acute kidney injury an important consideration as the cause of hyperkalemia. Acute kidney injury can develop from decreased intravascular volume associated with hypoaldosteronism and this can usually be treated with isotonic fluid resuscitation.⁷

The use of perindopril could give rise to type 4 hyperkalemic RTA, in which ACEI decreases the production of aldosterone by inhibiting the conversion of angiotensin I to angiotensin II, giving a normal-to-high renin level and low aldosterone levels. However, stopping perindopril did not appear to resolve the issue of hyperkalemia which made type 4 RTA secondary to perindopril unlikely to be the culprit.

With the persistent hyperkalemia, another plausible differential diagnosis included type 4 RTA secondary to diabetic nephropathy, a condition characterized by hyporeninemic hypoaldosteronism that is mediated by the destruction of the juxtaglomerular apparatus due to vascular hyalinosis.⁸ As his direct renin concentration was not low on follow-up and given that his T2DM was well-controlled (HbA1c 6.4%) on single oral glucose-lowering agent with lack of other target organ damage, type 4 RTA caused by diabetic nephropathy was considered to be less likely. Diagnosis of persistent hypoaldosteronism was made much later at 57 months post-adrenalectomy and this was supported by an undetectable plasma aldosterone level with a normal upright renin level in the presence of hyperkalemia.

The etiology of persistent hypoaldosteronism post adrenalectomy for unilateral primary aldosteronism has not been clear-cut. Among the possible mechanisms include decreased contralateral adrenal mass or atrophy of the zona glomerulosa cells due to chronic renin suppression, stunting of the contralateral adrenal gland from severe and prolonged disease duration, and that the sustained hypokalemia before adrenalectomy may have suppressed the aldosterone synthesis in the zona glomerulosa and prolonged the duration of hypoaldosteronism.^{3,9,10} Both hyporeninemic and hyperreninemic hypoaldosteronism have been described in patients with persistent post-operative hypoaldosteronism.¹ Irreversible damage to the juxtaglomerular apparatus from hypertension and/or other detrimental renal effects of aldosterone excess have been postulated to explain the hyporeninemic state post-adrenalectomy.¹ Nevertheless, renin deficiency was not the cause of sustained hypoaldosteronism in this case vignette where aldosterone production was still suppressed despite normalization of renin level. The dissociated renin and aldosterone levels reflected the underlying problem perhaps stemmed from defect in the synthetic capability of the contralateral adrenal gland. A study by Wada et al., also showed that renin concentration post-adrenalectomy was not significantly different between the persistent hypoaldosteronism group versus the group without this condition.¹¹ It is unknown how long persistent hypoaldosteronism may last given the limited longitudinal studies done on such patients, although in one of the literatures hyperkalemia was reported to occur even up to 46 months post-adrenalectomy.¹

Predictors of hyperkalemia post-adrenalectomy include older age, longer duration of hypertension, impaired renal function pre- and post-adrenalectomy, presence of microalbuminuria post-adrenalectomy, larger adrenal mass size on pathology and higher pre-operative aldosterone level.^{1-3,12} This patient had longstanding hypertension of 14 years prior to adrenalectomy, to which Park et al., found that duration of hypertension greater than 9.5 years was associated with 10.5 times higher risk of developing hyperkalemia.² This patient was 52 years old at the time of operation which was approximate to the older age cut-off of 53 years old as demonstrated by the same authors to pose higher risk for hyperkalemia post-adrenalectomy (odds ratio 15.6).² The normal creatinine level prior to operation did not rule out underlying renal disease as the excess aldosterone induces vasodilation in afferent and efferent arterioles, giving rise to intraglomerular hypertension and glomerular hyperfiltration, resulting in a seemingly normal renal function. In a large Italian PAPY trial by Rossi et al., the adjusted 24-hour urine albumin excretion rate, an early marker of renal injury was significantly higher in the patients with primary aldosteronism than in the essential hypertension group.¹³

Microalbuminuria was present in this patient prior to operation, indicating early renal involvement. The reversal of aldosterone-mediated hyperfiltration by adrenalectomy

unmasked the true extent of the underlying renal injury, which was manifested by a decline in GFR seen upon follow-up in this case. Adrenal mass size of more than 1.95 cm on pathology was seen to predict a higher risk of post-operative hyperkalemia (adjusted OR 5.78) and in this case, the size of the resected adrenal nodule was more than 1.95 cm at its widest dimension.² Contralateral gland suppression index (CSI) of less than 0.47 was found to have good sensitivity but low specificity (AUC 0.69, sensitivity 100% and specificity 28.9%) to predict post-operative hyperkalemia.¹⁴ CSI in this case was 0.33, reflecting a greater degree of contralateral adrenal gland suppression and therefore would need close monitoring of serum potassium post-operatively. The role of mineralocorticoid receptor antagonist in the development of post-operative hyperkalemia is controversial. Spironolactone was observed to have a direct inhibitory effect on adrenal steroidogenesis and long-term use had been associated with spontaneous remission of primary aldosteronism.¹⁵ However, few large studies concluded that pre-operative use of mineralocorticoid receptor antagonists in fact did not appear to influence the incidence of hypoaldosteronism or hyperkalemia.^{1,2} In this case, spironolactone was withheld more than 1 year prior to adrenalectomy and the seemingly short duration of use limited by adverse effect of gynecomastia made it unlikely to be the main cause of persistent hypoaldosteronism by mechanism of impairing aldosterone synthesis in this patient.

The Endocrine Society 2016 recommended withdrawing potassium supplementation and discontinuing spironolactone post-operatively and a generous sodium diet during the first few weeks after surgery.⁴ In addition to these preventive measures and instituting a low potassium diet, reversible causes should be addressed in high-risk patients such as hypovolemia, urinary tract obstruction and use of non-steroidal anti-inflammatory drugs and RAAS inhibitors which can contribute to or aggravate hyperkalemia by reducing further an already impaired GFR.¹² In our case, the continuity of ACEI and potassium supplementation albeit at a lower dose could have contributed to the severity of hyperkalemia on top of the potentiating effect of hypoaldosteronism. Monitoring of electrolytes post adrenalectomy has not been standardized. Tahir et al., advocated potassium monitoring at day 2, 14 and 28 post-operation for high-risk groups and monthly monitoring thereafter for mild hyperkalemia (potassium <5.5 mmol/L) till it resolves.¹² Pharmacological therapies for more severe hyperkalemia, i.e., potassium more than 5.5 mmol/L include fludrocortisone, sodium bicarbonate, loop diuretics and potassium binders with treatment choice tailored according to volume status, blood pressure and renal function.¹² Limited by the movement restrictions during the COVID-19 pandemic in 2020, electrolyte monitoring was done at four- to five-month intervals after the initial post-operative clinic review. This may have resulted in delay in the detection of hyperkalemia only at 10 months post adrenalectomy.

Fludrocortisone is the drug-of-choice for the treatment of persistent hypoaldosteronism in this case given the protracted course of disease and absence of contraindications. Few case studies reported successes after stopping pharmacological therapies at certain point in time with resolution of hyperkalemia or symptomatology related to hypoaldosteronism, while others were unsuccessful due to the recurrences of electrolyte abnormalities such as hyperkalemia, hyponatremia with or without increment in creatinine level.^{9,10,12,16-18} Long-term use of fludrocortisone is limited by side effects such as hypertension, peripheral edema and worsening heart failure in those with pre-existing cardiovascular disease.¹² Mineralocorticoid replacement, if indicated, should be administered in physiological doses to avoid hypervolemia and associated suppression of renin and aldosterone secretion.⁵ Taniguchi et al., recommended mineralocorticoid replacement to be used as short-term, if possible, to avoid retarding the recovery of the contralateral adrenal to synthesize aldosterone.¹⁹ Further discussions with the patient regarding the optimal timing for fludrocortisone discontinuation to permit recovery of endogenous renin and aldosterone production are required, while carefully weighing the risks and benefits of long-term fludrocortisone therapy.

CONCLUSION

With the increasing number of adrenalectomies done for unilateral primary aldosteronism, clinicians need to be familiar with the potential complications that may arise from the operations, mainly hypoaldosteronism leading to hyperkalemia which may be accompanied by other electrolytes and hemodynamic perturbations. Certain risk factors predispose to post-operative hyperkalemia and identification of such risk factors would warrant close monitoring and implement early preventive measures to prevent catastrophic complications or morbidities. The vast benefits of surgery in unilateral primary aldosteronism should not be offset by the resulting hypoaldosteronism that follows the reversal of aldosterone excess. Optimal duration of mineralocorticoid replacement to date remains unclear. Treatment for hyperkalemia resulting from persistent hypoaldosteronism is not standardized and is largely based on anecdotal reports. More studies would be needed to formulate guidelines on treatment and follow-up on cases of persistent hypoaldosteronism and to identify biomarkers to predict recovery of aldosterone secretion in such challenging cases. This case report highlights the importance of close monitoring of serum potassium, early recognition and timely initiation of appropriate treatment for persistent hypoaldosteronism following unilateral adrenalectomy for primary aldosteronism.

PATIENT PERSPECTIVE

"I'm glad that I no longer need to follow any dietary restrictions since starting on fludrocortisone. Although I experienced leg swelling at the beginning of the treatment, it resolved after furosemide was added. My doctor recently told me that my kidney function has improved, and I haven't needed any hospitalization for high potassium levels over the past year. Overall, I am satisfied with the management."

Acknowledgments

Special acknowledgments to the entire Endocrinology team and Pathology Department from Sultanah Bahiyah Hospital for the support.

Ethical Consideration

Patient consent forms were obtained before manuscript submission.

Statement of Authorship

All authors certified fulfillment of ICMJE authorship criteria.

CRedit Author Statement

JET: Conceptualization, Methodology, Validation, Formal analysis, Investigation, Data Curation, Writing – original draft preparation, Writing – review and editing, Visualization, Project administration; **NSYAM:** Validation, Writing – review and editing, Supervision; **SI:** Validation, Writing – review and editing, Supervision; **NRAA:** Validation, Writing – review and editing, Supervision.

Data Availability Statement

No datasets were generated or analyzed for this study.

Author Disclosure

The authors declared no conflict of interest.

Funding Source

None.

References

- Fischer E, Hanslik G, Pallauf A, et al. Prolonged zona glomerulosa insufficiency causing hyperkalemia in primary aldosteronism after adrenalectomy. *J Clin Endocrinol Metab.* 2012;97(11):3965-73. PMID: 22893716 DOI: 10.1210/jc.2012-2234
- Park KS, Kim JH, Ku EJ, et al. Clinical risk factors of postoperative hyperkalemia after adrenalectomy in patients with aldosterone-producing adenoma. *Eur J Endocrinol.* 2015;172(6):725-31. PMID: 25766046 DOI: 10.1530/EJE-15-0074
- Chiang WF, Cheng CJ, Wu ST, et al. Incidence and factors of post-adrenalectomy hyperkalemia in patients with aldosterone producing adenoma. *Clin Chim Acta.* 2013;424:114-8. PMID: 23727469 DOI: 10.1016/j.cca.2013.05.017
- Funder JW, Carey RM, Mantero F, et al. The management of primary aldosteronism: Case detection, diagnosis, and treatment: An Endocrine Society clinical practice guideline. *J Clin Endocrinol Metab.* 2016;101(5):1889-916. PMID: 26934393 DOI: 10.1210/jc.2015-4061
- Biglieri EG, Slaton PE Jr, Silen WS, Galante M, Forsham PH. Postoperative studies of adrenal function in primary aldosteronism. *J Clin Endocrinol Metab.* 1966;26(5):553-8. PMID: 4287160 DOI: 10.1210/jcem-26-5-553
- Mermejo LM, Elias PCL, Molina CAF, et al. Early renin recovery after adrenalectomy in aldosterone-producing adenomas: A prospective study. *Horm Metab Res.* 2022;54(4):224-31. PMID: 35413743 DOI: 10.1055/a-1778-4002
- Hajmomenian HR. Hyperkalemia following unilateral adrenalectomy for adrenal adenoma. *Proc UCLA Health.* 2013;17. <https://escholarship.org/uc/item/2n7208zw>
- Mustaqeem R, Arif A. Renal tubular acidosis. *StatPearls.* Treasure Island (FL): StatPearls Publishing; 2026.

9. Hyland K, Perkins J. Persistent hyperkalemia status postadrenalectomy for primary aldosteronism. *Endocr Pract.* DOI: 10.4158/EP15812. CR Corpus ID: 57152028
10. Angus LM, Yang J, Cheung AS. Persistent hypoaldosteronism post-adrenalectomy for primary aldosteronism: A role for pre-operative spironolactone? *Endocrinol Diabetes Metab Case Rep.* 2021;2021:21-0137. PMID: 34695011 PMCID: PMC8558879 DOI: 10.1530/EDM-21-0137
11. Wada N, Baba S, Sugawara H, et al. Prolonged postoperative hypoaldosteronism related to hyperkalemia in patients with aldosterone-producing adenoma. *Endocr J.* 2023;70(9):917-24. PMID: 37423737 DOI: 10.1507/endocrj.EJ23-0174
12. Tahir A, McLaughlin K, Kline G. Severe hyperkalemia following adrenalectomy for aldosteronoma: Prediction, pathogenesis and approach to clinical management: A case series. *BMC Endocr Disord.* 2016;16(1):43. PMID: 27460219 PMCID: PMC4962422 DOI: 10.1186/s12902-016-0121-y
13. Rossi GP, Bernini G, Desideri G, et al. Renal damage in primary aldosteronism: Results of the PAPY Study. *Hypertension.* 2006;48(2):232-8. PMID: 16801482 DOI: 10.1161/01.HYP.0000230444.01215.6a
14. Shariq OA, Bancos I, Cronin PA, et al. Contralateral suppression of aldosterone at adrenal venous sampling predicts hyperkalemia following adrenalectomy for primary aldosteronism. *Surgery.* 2018;163(1):183-90. PMID: 29129366 DOI: 10.1016/j.surg.2017.07.034
15. Mai X, Kometani M, Yoneda T. Spontaneous remission of primary aldosteronism with mineralocorticoid receptor antagonist therapy: A review. *Int J Mol Sci.* 2022;23(22):13821. PMID: 36430298 PMCID: PMC9698409 DOI: 10.3390/ijms232213821
16. Gadallah MF, Kayyas Y, Boules F. Reversible suppression of the renin-aldosterone axis after unilateral adrenalectomy for adrenal adenoma. *Am J Kidney Dis.* 1998;32(1):160-3. PMID: 9669438 DOI: 10.1053/ajkd.1998.v32.pm9669438
17. Starker LF, Christakis I, St Julien J, et al. Considering postoperative functional hypoaldosteronism after unilateral adrenalectomy. *Am Surg.* 2017;83(6):598-604. PMID: 28637561
18. Yorke E, Stafford S, Holmes D, et al. Aldosterone deficiency after unilateral adrenalectomy for Conn's syndrome: A case report and literature review. *Int J Surg Case Rep.* 2015;7C:141-4. PMID: 25604311 PMCID: PMC4336421 DOI: 10.1016/j.ijscr.2015.01.013
19. Taniguchi R, Koshiyama H, Yamauchi M, et al. A case of aldosterone-producing adenoma with severe postoperative hyperkalemia. *Tohoku J Exp Med.* 1998;186(3):215-23. PMID: 10348217 DOI: 10.1620/tjem.186.215

Authors are required to accomplish, sign and submit scanned copies of the JAFES Author Form consisting of: (1) Authorship Certification, that authors contributed substantially to the work, that the manuscript has been read and approved by all authors, and that the requirements for authorship have been met by each author; (2) the Author Declaration, that the article represents original material that is not being considered for publication or has not been published or accepted for publication elsewhere, that the article does not infringe or violate any copyrights or intellectual property rights; that no references have been made to predatory/suspected predatory journals; and that use of artificial intelligence (AI) or AI-assisted technologies shall be declared to include the name of the AI tool or service used; (3) the Author Contribution Disclosure, which lists the specific contributions of authors; (4) the Author Publishing Agreement which retains author copyright, grants publishing and distribution rights to JAFES, and allows JAFES to apply and enforce an Attribution-Non-Commercial Creative Commons user license; and (5) the Conversion to Visual Abstracts (*optional for original articles only) to improve dissemination to practitioners and lay readers. Authors are also required to accomplish, sign, and submit the signed ICMJE form for Disclosure of Potential Conflicts of Interest. For original articles, authors are required to submit a scanned copy of the Ethics Review Approval of their research as well as registration in trial registries as appropriate. For manuscripts reporting data from studies involving animals, authors are required to submit a scanned copy of the Institutional Animal Care and Use Committee approval. For Case Reports or Series, and Images in Endocrinology, consent forms, are required for the publication of information about patients; otherwise, appropriate ethical clearance has been obtained from the institutional review board. Articles and any other material published in the JAFES represent the work of the author(s) and should not be construed to reflect the opinions of the Editors or the Publisher.



**Unique, interesting, enlightening.
Your case report and the JAFES.**